Contents

Chapter 10: Muscles of the Pelvis and Thigh, 339

Chapter 11: Muscles of the Leg and Foot, 385

Preface

Know the Body: Muscle, Bone, and Palpation Essentials, is meant to be the best single source for all the essential knowledge about the musculoskeletal system that a massage therapist or any manual or movement therapist needs. Attachments (origins and insertions), actions (regular and stabilization functions), and palpation are covered for all the major muscles and muscle groups of the body, as well as applications to treatment. In addition, this book contains five introductory chapters that cover basic kinesiology terminology, bones and bony landmarks, how muscles function, how to palpate, and palpation of bones and bony landmarks. All the essentials that you need to know are contained in this one book, along with online demonstration videos on how to palpate individual muscles and an interactive CD at the back of the book that allows the viewer to place any combination of muscles on the skeleton to learn not just each individual muscle, but also the relative relationship of muscles!

WHO WILL BENEFIT FROM THIS BOOK?

This book is written primarily for students and practicing therapists of manual and movement therapies, including massage therapy, physical therapy, occupational therapy, chiropractic, osteopathy, orthopedics, athletic training, yoga, Pilates, and Feldenkrais. However, anyone who needs to learn the skeletal muscles of the body will find this book invaluable and an essential resource. This book will be your guide as you first learn the muscles of the body, and it will remain an invaluable resource on your bookshelf for as long as you are in practice.

CONCEPTUAL APPROACH

The approach taken by *Know the Body: Muscle, Bone, and Palpation Essentials* is to clearly and concisely present all the essential information that needs to be learned about the musculoskeletal system. The beginning chapters set the framework for how muscles work and how to palpate, as well as offer a five-step approach to learning muscles. The later chapters then provide the application of this knowledge to the bones and muscles of the body. The goal of this book is to enable the student, therapist, trainer, or physician to be able to critically think through muscle functioning when working clinically with clients and patients.

ORGANIZATION

Know the Body is organized into two major parts.

Part One

Chapter 1 covers all the essential kinesiology terminology that a therapist needs to be able understand and communicate about the musculoskeletal system.

Chapter 2 is an atlas of the skeletal system, covering all the bones, bony landmarks, muscle attachment sites, and joints of the body.

Chapter 3 is a critically important chapter because it explains clearly and concisely how the muscular system functions. This chapter not only provides a strong foundation to be able to learn the muscles of the body, but it also teaches the reader to critically think through muscle function and apply it in clinical settings.

Chapter 4 is another critically important chapter because it teaches the art and science of palpation. With the knowledge presented in this chapter, the therapist will learn how to reason through muscle palpation protocols instead of simply memorizing them.

Chapter 5 is an atlas of palpation of the bones and major bony landmarks of the body—all with clear and simple illustrations.

Part Two

Chapters 6 through 11 are the meat of this book. They divide the body into regions and cover all the essentials for every major muscle and muscle group within the region. Each chapter contains beautiful cutting-edge illustrations of the muscles of the region drawn onto a skeleton and placed over a photograph of a real person. Functional guidelines present how to reason through the actions of the groups of muscles presented. Each muscle or muscle group are then presented individually, with attachments (origins and insertions), actions, stabilization functions, innervation, palpation, and

treatment considerations given. Review questions and case studies are also provided at the end of each chapter.

Chapter 6 covers the muscles of the shoulder girdle and arm.

Chapter 7 covers the muscles of the forearm and hand.

Chapter 8 covers the muscles of the spine and rib cage.

Chapter 9 covers the muscles of the head.

Chapter 10 covers the muscles of the pelvis and thigh.

Chapter 11 covers the muscles of the leg and foot.

An illustrated stretching atlas concludes the book, featuring drawings of stretches for all major muscles.

DISTINCTIVE FEATURES

Know the Body has many distinctive features:

- The most thorough yet concise muscle atlas for attachments, actions, and palpation
- Palpation of the bones and bony landmarks
- Explanations and guidelines that promote critical thinking to understand muscle actions
- Beautiful illustrations in which the bones and muscles are placed on a photograph of a real person
- Large group illustrations for every functional muscle group
- Online video coverage of the palpation protocols for individual muscles of the body
- Treatment considerations for application to clinical settings
- An interactive CD that allows for any combination of muscles to be placed on the skeleton and body

LEARNING AIDS

- *Know the Body* is meant to be used not only as a textbook but also as an in-class manual.
- Arrows are placed over the muscle for each individual muscle illustration so that the line of pull of the muscle can be seen and visually understood. This feature allows for the actions of the muscle to be understood instead of memorized.
- A "Treatment Considerations" section is provided that offers interesting insights to each muscle. Many of these are clinical applications that flesh out and make learning the muscle more interesting.
- Review questions and case studies are placed at the end of each chapter to help the reader grasp how well he or she understands the content.
- A companion student workbook is available that provides multiple learning exercises and follows *Know the Body: Muscle, Bone, and Palpation Essentials*, chapter for chapter.

COMPANION CD

Know the Body includes a unique, interactive CD. A base photograph of the region of the body is presented with the skeleton drawn in. A list of every muscle of that region is given; and you can choose any combination of muscles and place them onto the illustration, allowing you to not only see that muscle's attachments, but, more importantly, to be able to see the relationship between all the muscles of the region. Any combination of muscles can be chosen!

EVOLVE ONLINE RESOURCES

Know the Body is supported by an Evolve website that includes the following student resources:

- Downloadable audio pronunciations of muscle names, attachments, and actions
- Palpation video clips covering skeletal muscles of the human body
- Crossword puzzles
- Bony palpation matching activities
- Electronic coloring book

Access these resources at http://evolve.elsevier.com/Muscolino/knowthebody.

RELATED PUBLICATIONS

Know the Body: Muscle, Bone, and Palpation Essentials is supported by an excellent student workbook, *Workbook for Know the Body*, that provides multiple learning exercises for learning the content. Not only does the student workbook follow *Know the Body* chapter by chapter, providing cross reference page numbers for all of the content covered by the exercises, each chapter of the workbook is divided into sections that amount to roughly 1 week's amount of content. This workbook allows for periodic and regular review of the material being learned!

For more information on the musculoskeletal system, see Dr. Joe Muscolino's other publications:

- *The Muscular System Manual: The Skeletal Muscles of the Human Body*, third edition: the most thorough muscle atlas on the market.
- *Kinesiology: The Skeletal System and Muscle Function*, second edition: the most straightforward and thorough book on how the musculoskeletal system functions written for manual and movement therapists.
- *The Muscle and Bone Palpation Manual: With Trigger Points, Referral Patterns, and Stretching:* the authoritative guide to muscle palpation, trigger points, and stretching.

- *Musculoskeletal Anatomy Flashcards*, second edition: supports *The Muscular System Manual: The Skeletal Muscles of the Human Body*, third edition.
- *Flashcards for Bones, Joints, and Actions of the Human Body*, second edition: supports *Kinesiology: The Skeletal System and Muscle Function*, second edition.
- *Flashcards for Palpation, Trigger Points, and Referral Patterns:* supports *The Muscle and Bone Palpation Manual: With Trigger Points, Referral Patterns, and Stretching.*
- *Mosby's Trigger Point Flip Chart, with Referral Patterns and Stretching.*

NOTE TO THE STUDENT

Learning the musculoskeletal system can often feel overwhelming at first. This book presents the content in an approachable manner that will make learning this material fun! It also presents the content in a clear and straightforward manner that encourages you to think through the content so that you better understand it and can apply it to your clients when you are in practice. This makes learning not just fun and easy but better! Whether as an in-class manual or a reference text for your bookshelf, you will find this book to be an ideal and essential book now and into the future!

AXES

An *axis* (plural: *axes*) is an imaginary line around which a body part moves. If a body part moves in a circular path around an axis, it is described as an axial motion. If the body part moves in a straight line, it is described as a nonaxial motion. Both axial and nonaxial motions of a body part move within a plane. However, an axial motion moves within a plane and moves around an axis. The orientation of an axis for movement is always perpendicular to the plane within which the movement is occurring.

Each plane has its own corresponding axis; therefore there are three cardinal axes. The axis for sagittal plane movements is oriented side to side and described as the mediolateral axis, the axis for frontal plane movements is oriented front to back and described as anteroposterior, and the axis for transverse plane movements is oriented up and down and described as superoinferior or simply vertical. Each oblique plane also has its own corresponding axis, which is perpendicular to it. Figure 1-6 illustrates axial motions that occur within planes and around their corresponding axes.

MOVEMENT TERMINOLOGY

Using anatomic position, we are able to define terms that describe static locations on the body. We now need to define terms that describe dynamic movements of the body. These movement terms are called *joint actions*. Similar to location terms, they come in pairs in which each member of the pair is the opposite of the other (Box 1-3). However, different from location terms, movement terms do not describe a static location; rather, they describe a direction of motion. The major pairs of joint action terms are defined here.

It should be noted that joint actions usually describe cardinal plane motions of a body part. For example, the brachialis muscle brings the forearm anteriorly in the sagittal plane at the elbow joint; therefore its action is described as flexion of the forearm at the elbow joint. If a muscle creates an oblique plane motion, then this motion is described by breaking it into its component cardinal plane joint action motions. An example is the coracobrachialis muscle, which moves the arm anteriorly (in the sagittal plane) and medially (in the frontal plane). When describing this motion, it is said that the coracobrachialis flexes and adducts the arm at the

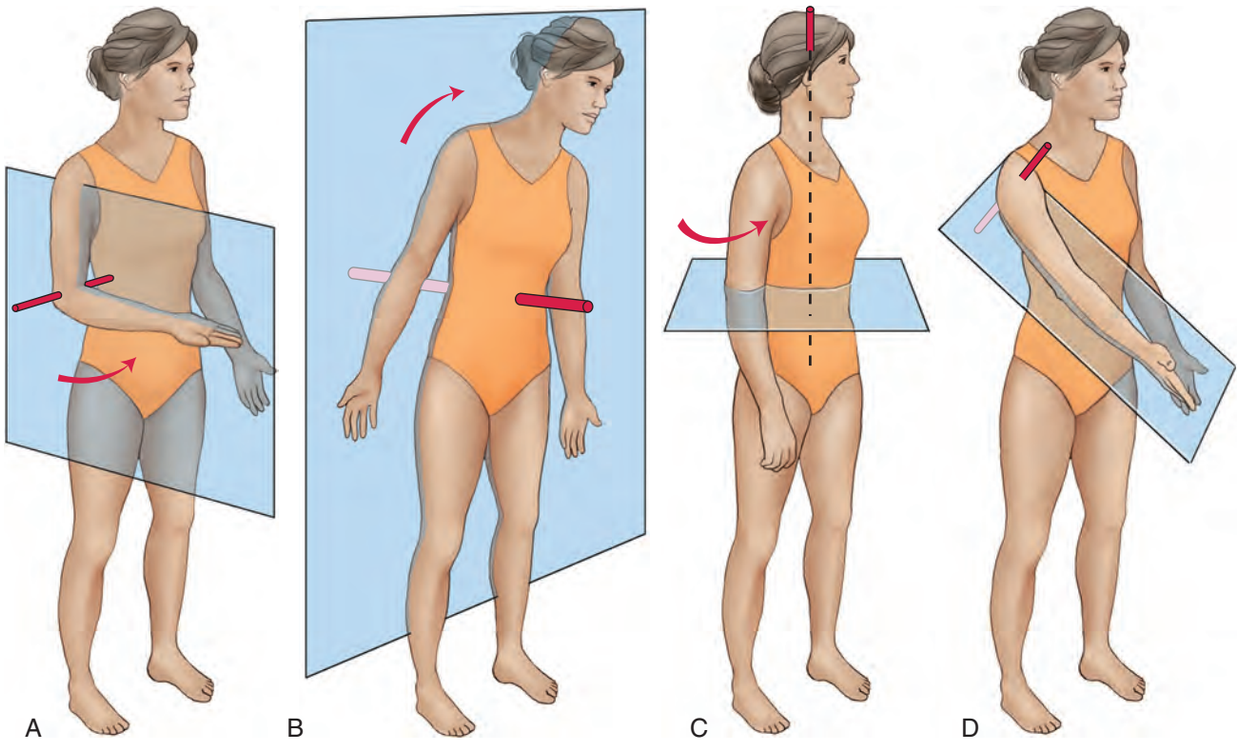

FIGURE 1-6 Anterolateral views illustrate the corresponding axes for the three cardinal planes and an oblique plane; the axes are shown as red tubes. Note that an axis always runs perpendicular to the plane in which the motion is occurring. ***A,*** Motion occurring in the sagittal plane around the mediolateral axis. ***B,*** Motion occurring in the frontal plane around the anteroposterior axis. ***C,*** Motion occurring in the transverse plane around the superoinferior axis or, more simply, the vertical axis. ***D,*** Motion occurring in an oblique plane around an axis that is running perpendicular to that plane (i.e., it is the oblique axis for this oblique plane).

Forearm at the Elbow and Radioulnar Joints

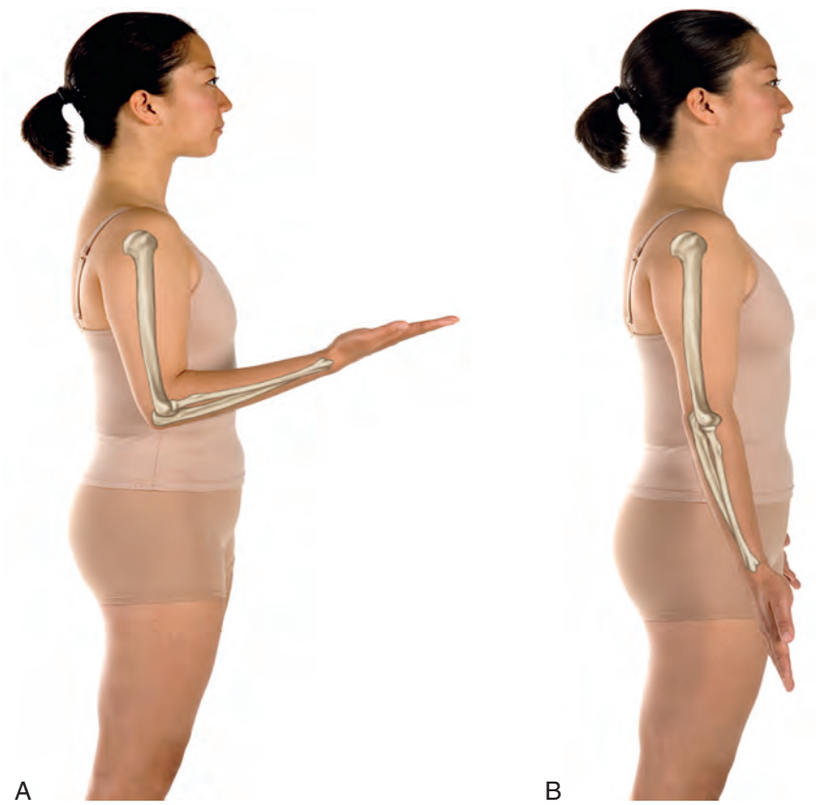

FIGURE 1-17 Motions of the right forearm at the elbow joint. ***A,*** Flexion. ***B,*** Extension. (Note: Both views are lateral.)

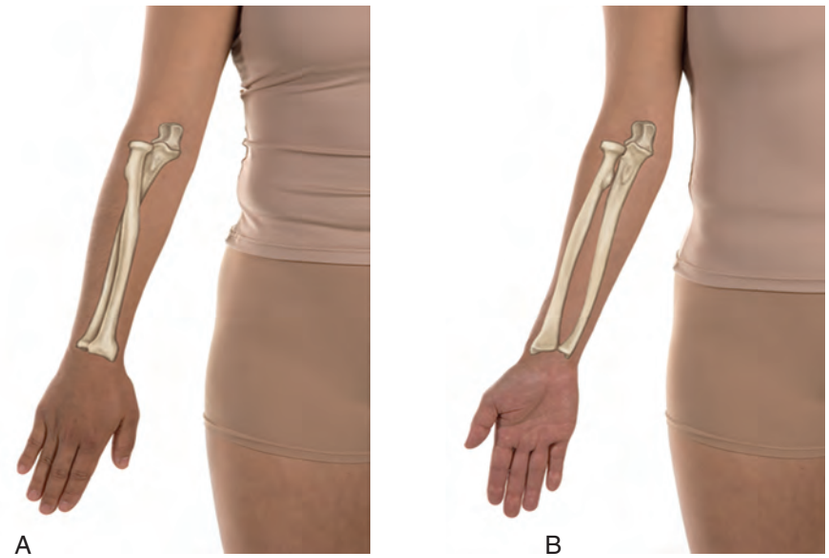

FIGURE 1-18 Pronation and supination of the right forearm at the radioulnar joints. ***A,*** Pronation. ***B,*** Supination, which is anatomic position for the forearm. (Note: Both views are anterior.)

Leg at the Knee Joint

FIGURE 1-33 Motions possible at the right tibiofemoral (i.e., knee) joint. ***A*** and ***B,*** Lateral views illustrate flexion and extension of the right leg at the knee joint, respectively. ***C*** and ***D,*** Anterior views illustrate lateral and medial rotation of the right leg at the knee joint, respectively. (Note: The knee joint can only rotate if it is first flexed.)

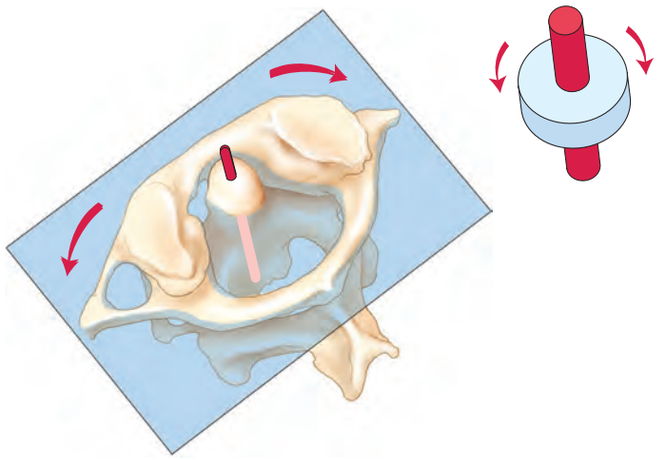

FIGURE 2-5 The atlantoaxial (C1-C2) joint of the spine between the atlas and axis is an example of a synovial, uniaxial pivot joint. It allows right and left rotations within the transverse plane around a vertical axis.

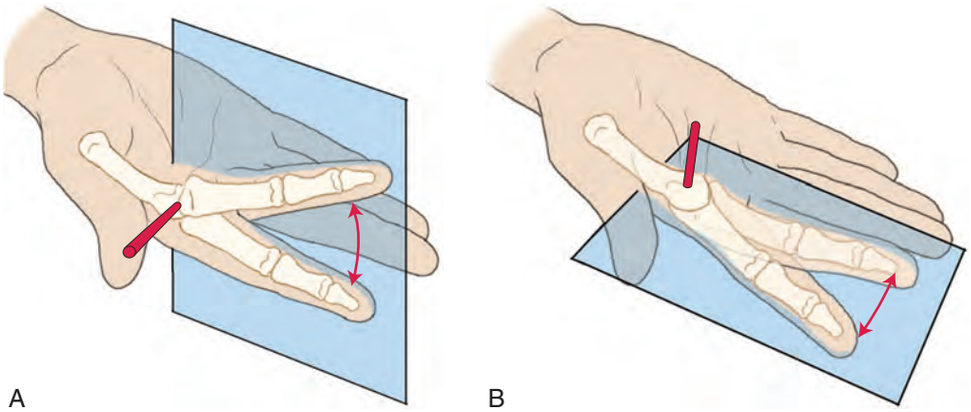

FIGURE 2-6 The metacarpophalangeal joint of the hand is an example of a synovial, biaxial condyloid joint. It allows flexion and extension in the sagittal joint around a mediolateral axis ***(A)*** and abduction and adduction in the frontal plane around an anteroposterior axis ***(B).***

Triaxial Joints

There is only one major type of synovial triaxial joint: ball-and-socket. As its name implies, one bone is shaped like a ball and fits into the socket shape of the other bone. A ball-and-socket joint allows the following motions: flexion and extension in the sagittal plane around a mediolateral axis; abduction and adduction in the frontal plane around an anteroposterior axis; and medial rotation and lateral rotation in the transverse plane around a vertical axis. The hip joint is a classic example of a ball-and-socket joint (Figure 2-8).

Nonaxial Joints

Synovial nonaxial joints permit motion within a plane, but the motion is a linear gliding motion and not a circular (axial) motion around an axis. The surfaces of nonaxial joints are usually flat or curved. Intercarpal joints between individual carpal bones of the wrist are examples of nonaxial joints (Figure 2-9).

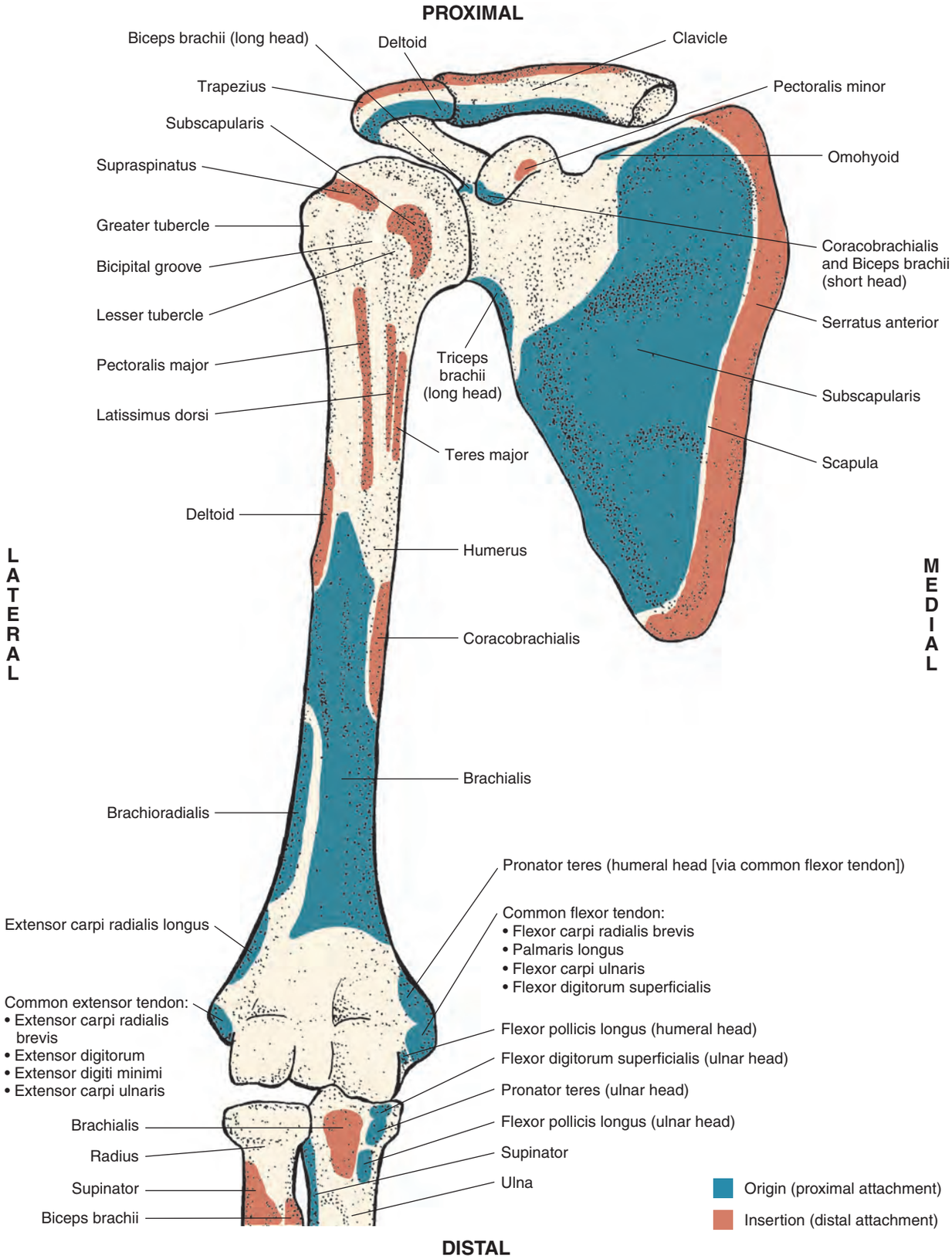

FIGURE 2-11 Anterior view of muscle attachment sites on the right scapula/arm.

How Muscles Function

CHAPTER 3

CHAPTER OUTLINE

MUSCLES CREATE PULLING FORCES

The essence of muscle function is that muscles create pulling forces. It is as simple as that. When a muscle contracts, it *attempts* to pull in toward its center. This action results in a pulling force being placed on its attachments. If this pulling force is sufficiently strong, the muscle will succeed in shortening and will move one or both of the body parts to which it is attached. Realizing that this pulling force is equal on both of its attachments is also important. A muscle does not and cannot choose to pull on one of its attachments and not the other. In effect, a muscle is nothing more than a simple "pulling machine." When ordered to contract by the nervous system, it pulls on its attachments; when not ordered to contract, it relaxes and does not pull (Box 3-1).

Determining whether there is a cognate (i.e., a *similar term* in lay English) is usually extremely helpful when confronted with a new kinesiology term. This helps us understand the new kinesiology term intuitively instead of having to memorize its meaning. When it comes to the study of muscle function, the operative word is *contract* because that is what muscles do. However, in this case, it can be counterproductive to try to understand muscle contraction by relating it to how the term *contract* is defined in English. In English, the word "contract" means "to shorten." This leads many students to assume that when a muscle contracts, it shortens. This is not necessarily true, and making this assumption can limit our ability to truly grasp how the muscular system functions. In fact, most muscle contractions do not result in the muscle shortening; to examine the muscular system in this way is to overlook much of how the muscular system functions.

BOX 3-1

To call a muscle nothing more than a simple "pulling machine" does not lessen the amazing and awe-inspiring complexity of movement patterns that the muscular system produces. Any one muscle is a simple machine that pulls. However, when different aspects of various muscles are co-ordered to contract in concert with each other and in temporal sequence with one another, the sum of many "simple" pulling forces results in an amazingly fluid and complex array of movement patterns. The director of this symphony who coordinates these pulling forces is the nervous system.

Sarcomeres are composed of thin and thick filaments. The thin filaments are *actin* and are arranged on both sides of the sarcomere and attach to the *Z-lines*, which are the borders of the sarcomere. The thick filament is a *myosin* filament and is located in the center and contains projections called heads. When a stimulus from the nervous system is sent to the muscle, binding sites on the actin filaments become exposed and the myosin heads attach onto them, creating *cross-bridges*. The myosin heads then attempt to bend in toward the center of the sarcomere, creating a pulling force on the actin filaments. If the pulling force is sufficiently strong, the actin filaments will be pulled in toward the center of the sarcomere, sliding along the myosin filament, hence the name *sliding filament mechanism*. This will cause the Z-lines to be pulled in toward the center and the sarcomere will shorten (Figure 3-9).

Whatever happens to one sarcomere happens to all the sarcomeres of all the myofibrils of the muscle fiber. If we extrapolate this concept, we see that if all the sarcomeres of a myofibril shorten, then the myofibril itself will shorten. If all the myofibrils of a muscle fiber shorten, then the muscle fiber will shorten. If enough muscle fibers shorten, then the muscle itself will shorten, pulling one or both of its attachments in toward the center, causing motion of the body. This is how a concentric contraction occurs.

When a muscle's contraction is said to create a pulling force toward its center, that pulling force is the sum of the bending forces of all the myosin heads. If the sum of these forces is greater than the resistance to shortening, then the actin filaments will be pulled in toward the center of the sarcomere and a concentric contraction occurs. If the sum of these forces is less than the resistance to shortening, then the actin filaments will be pulled away from the center of the sarcomere and an eccentric contraction occurs. If the sum of the forces of the myosin heads is equal to the resistance force, then the actin filaments will not move and an isometric contraction occurs. Therefore the definition of muscle contraction is having myosin heads creating cross-bridges and pulling on actin filaments.

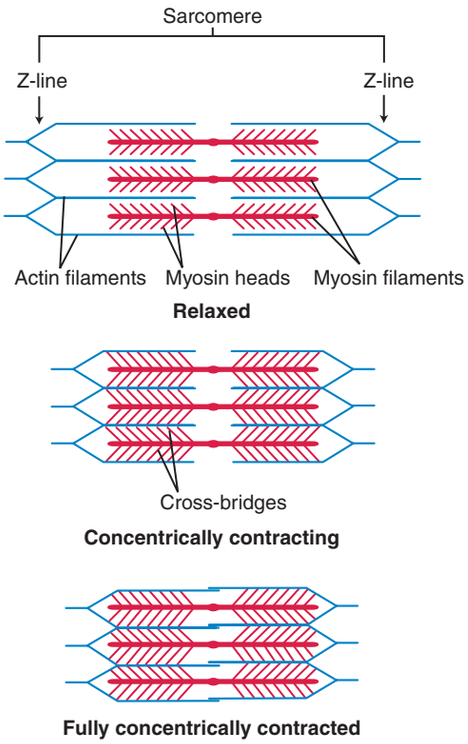

FIGURE 3-9 A sarcomere is composed of actin and myosin filaments. When the nervous system orders a muscle fiber to contract, myosin heads attach to actin filaments, attempting to pull them in toward the center of the sarcomere. If the pulling force is strong enough, the actin filaments will move and the sarcomere will shorten.

MUSCLE FIBER ARCHITECTURE

Not all muscles have their fibers arranged in the same manner. There are two major architectural types of muscle fiber arrangement: (1) longitudinal and (2) pennate. A longitudinal muscle has its fibers running along the length of the muscle. A pennate muscle has its fibers running obliquely to the length of the muscle. The major types of longitudinal muscles are demonstrated in Figure 3-10. The major types of pennate muscles are demonstrated in Figure 3-11.

LEARNING MUSCLES

- Essentially, when learning about muscles, two major aspects must be learned: (1) the attachments of the muscle and (2) the actions of the muscle.
- Generally speaking, the attachments of a muscle must be memorized. However, times exist when clues are given about the attachments of a muscle by the muscle's name.
  - For example, the name *coracobrachialis* tells us that the coracobrachialis muscle has one attachment on the coracoid process of the scapula and the other attachment on the brachium (i.e., the humerus).
  - Similarly, the name *zygomaticus major* tells us that this muscle attaches onto the zygomatic bone (and is bigger than another muscle called the *zygomaticus minor*).
- Unlike muscle attachments, muscle actions do not have to be memorized. Instead, by understanding the simple concept that a muscle pulls at its attachments to move a body part, the action or actions of a muscle can be reasoned out.

WHAT IS PALPATION?

Palpation may be defined in many ways. The word *palpation*, itself, derives from the Latin *palpatio*, which means "to touch." However, defining palpation as simply touching is too simplistic because more is involved. Inherent in the term *palpation* is not just touching but also the act of sensing or perceiving what is being touched. In this context, palpation involves more than just the fingers and hands. Palpation also involves the mind. Successful palpation requires us to feel with our brains, as well as with our fingers. When palpating, the therapist should be focused with a mindful intent; in other words, the therapist must be in his or her hands. All of the therapist's correlated knowledge of anatomy must be integrated into the sensations that the therapist's fingers are picking up from the client's body and sending to his or her brain. The therapist's mind must be open to the sensations that are coming in from the client, yet, at the same time, interpret these sensations with an informed mind (Figure 4-1). Incorporating mindful intent into examination and treatment sessions creates mindful touch.

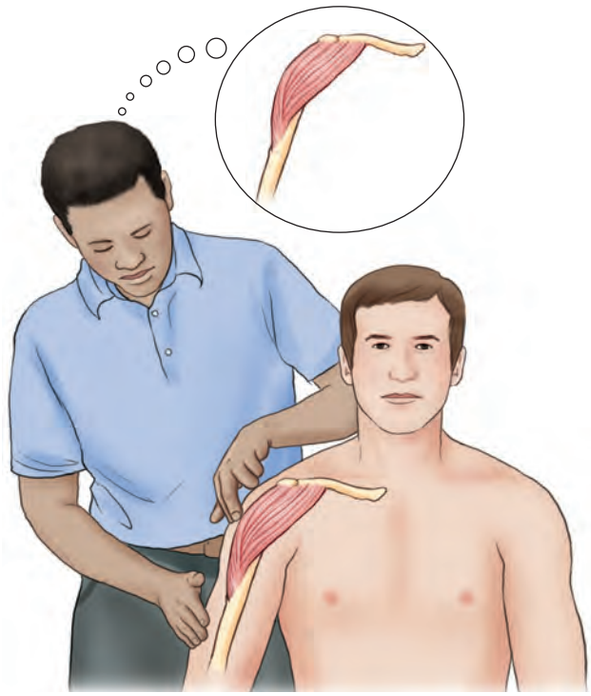

FIGURE 4-1 Palpation is as much an act of the mind as it is of the palpating fingers. Sensory stimuli entering through the therapist's hands must be correlated with a knowledge base of anatomy.

OBJECTIVES OF PALPATION: LOCATION AND ASSESSMENT

There are two main objectives when palpating. Objective 1 is locating the target structure. Objective 2 is assessing the target structure.

The first objective, and indeed perhaps the major objective of the novice therapist, is to locate the target structure being palpated. This feat is not easy to achieve. It is one thing to simply touch the tissues of the client. It is an entirely different matter to be able to touch the tissues and discern the target structure from all the adjacent tissues. This ability requires the therapist to locate all borders of the structure—superiorly, inferiorly, medially, laterally, and even superficially and deep. If the structure is immediately superficial to the skin, then this feat may not be very difficult. Indeed, the olecranon process of the ulna or a well-developed deltoid muscle may be visually obvious and located without even touching the client's body. However, if the target structure is deeper in the client's body, then locating the structure may present a great challenge.

As basic as palpation for the purpose of determining location may seem, it is a supremely important first objective because it follows that if a structure cannot be accurately located and discerned from adjacent tissues, then it cannot be accurately assessed. Once the target structure is located, then the process of assessment can begin. Assessment requires the interpretation of the sensations that the palpating fingers pick up from the target structure. It involves becoming aware of the qualities of the target structure—its size, shape, and other characteristics. Is it soft? Is it swollen? Is it tense or hard? All of these factors must be considered when assessing the health of the target structure.

It is worthy of note that as high-tech diagnostic and assessment equipment continues to be developed in Western medicine, palpating hands remain the primary assessment tool of a manual therapist. Indeed, for a manual therapist, palpation—the act of gathering information through touch—lies at the very heart of assessment. Armed with both an accurate location and an accurate assessment of the health of the target structure through careful palpation, the therapist can develop an effective treatment plan that can be confidently carried out.

Note: As crucial as palpation is to assessment, it is still only one piece of a successful assessment picture. Visual observation, history, findings from specific orthopedic assessment procedures, and the client's response to treatment approaches must also be considered when developing an accurate client assessment.

the biceps brachii is also a supinator of the forearm, having the forearm pronated will reciprocally inhibit it from contracting; consequently, it will remain relaxed as the brachialis contracts to flex the forearm at the elbow joint. Thus we have achieved the goal of having an isolated contraction of our target muscle, the brachialis.

Another example of using the principle of reciprocal inhibition to isolate the contraction of a target muscle is palpating the scapular attachment of the levator scapulae. If we ask the client to elevate the scapula to contract and palpably harden the levator scapulae, the upper trapezius will also contract and harden, making it impossible to feel the levator scapulae at its scapular attachment deep to the upper trapezius. To stop the upper trapezius from contracting, ask the client to place the hand in the small of the back. This position of humeral extension and adduction requires downward rotation of the scapula at the scapulocostal joint. Because the upper trapezius is an upward rotator of the scapula, it will be reciprocally inhibited and stay relaxed. This position allows for an isolated contraction of and a successful palpation of the levator scapulae when the client is asked to elevate the scapula (Figure 4-12).

One important caution is provided when using the principle of reciprocal inhibition for a muscle palpation. When the client is asked to contract and engage the target muscle, the force of its contraction must be small. If the contraction is forceful, the client's brain will override the reciprocal inhibition reflex in an attempt to recruit as many muscles as possible for the joint action, and contraction of the muscle that was supposed to be reciprocally inhibited and relaxed will be the result. Once this other muscle contracts, it will likely block successful palpation of the target muscle. For example, when palpating for the brachialis, if flexion of the forearm at the elbow joint is performed forcefully, the biceps brachii will be recruited, making palpation of the brachialis difficult or impossible. Another example is palpating for the levator scapulae: if elevation of the scapula at the scapulocostal joint is performed forcefully, then the upper trapezius will be recruited, making palpation of the levator scapulae at its scapular attachment difficult or impossible.

Guideline 12: Use Appropriate Pressure

It is important to avoid being too heavy handed; sensitivity can be lost with excessive pressure. On the other hand, it is important to not be too light with your pressure either; some muscles are quite deep and require moderate-to-strong pressure to feel. Generally, when most new students have a difficult time palpating a target muscle, it is because their pressure is too light. Appropriate pressure means applying the optimal palpation pressure for each target muscle palpation (Figure 4-13).

Note: Occasionally, a deep muscle palpation is facilitated by extremely light pressure. If a muscle is so deep that its borders cannot be felt, then its location must be determined by feeling for the vibrations of its contraction through the tissues. This can only be felt with a very light touch.

Guideline 13: For Deep Palpations, Sink Slowly into the Tissue and Have the Client Breathe

All deep muscle palpations should be performed slowly. Although deep pressure can be uncomfortable for many clients, it is often accomplished quite easily if we work with the client as we palpate. Sinking slowly into the client's tissues and having

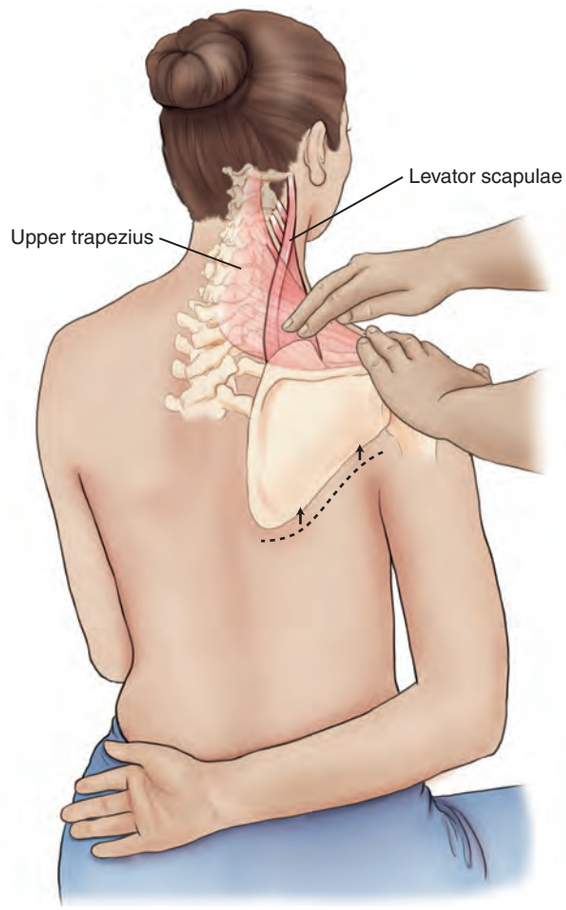

FIGURE 4-12 The principle of reciprocal inhibition is used to inhibit and relax the upper trapezius so that the scapular attachment of the levator scapulae can be more easily palpated as it contracts to elevate the scapula at the scapulocostal joint. The upper trapezius, which is also an upward rotator of the scapula, is reciprocally inhibited because the scapula is downwardly rotated (as it is elevated) because of the position of the hand in the small of the back.

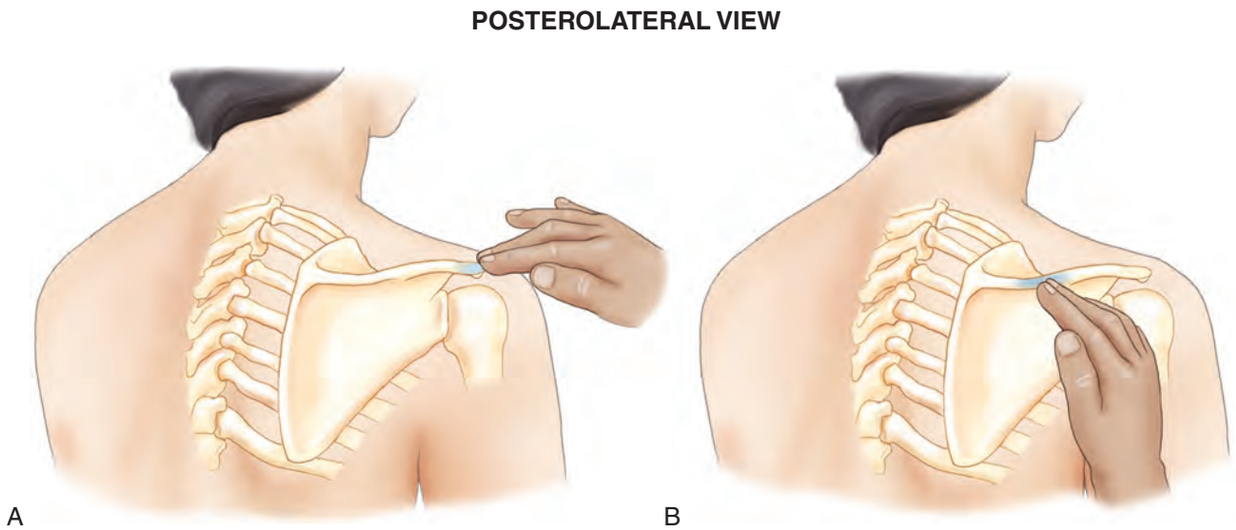

FIGURE 5-6 Acromion process and spine of the scapula: The **spine of the scapula** is the posterior continuation of the acromion process. To locate the spine of the scapula, begin on the acromion process ***(A),*** and continue palpating along it posteriorly. The spine of the scapula ***(B)*** can be palpated all the way to the medial border of the scapula. The spine of the scapula can be best palpated if you strum it perpendicularly by moving your palpating fingers up and down across it as you work your way posteriorly and then medially.

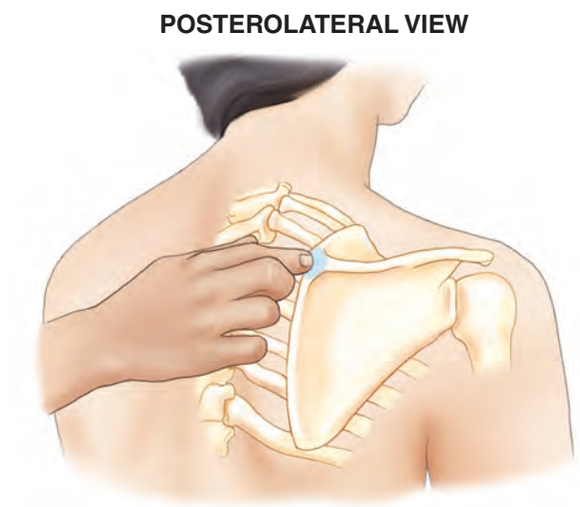

FIGURE 5-7 Medial border of the scapula (at the root of the spine of the scapula): Continue palpating along the spine of the scapula until you reach the **medial border of the scapula.** Where the spine of the scapula ends at the medial border is called the **root of the spine of the scapula.** Passively retracting the client's scapula makes it much easier to locate the medial border.

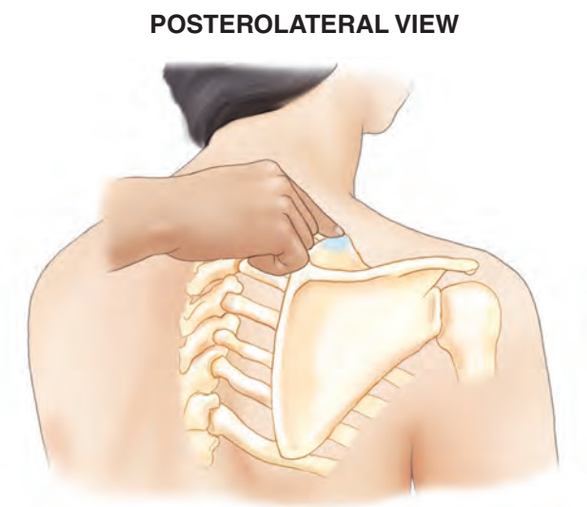

FIGURE 5-8 Superior angle of the scapula: Once the medial border of the scapula has been located, palpate along it superiorly until you reach the **superior angle of the scapula.** Having the client elevate and depress the scapula as you palpate for its superior angle can be helpful.

ANTEROLATERAL VIEW

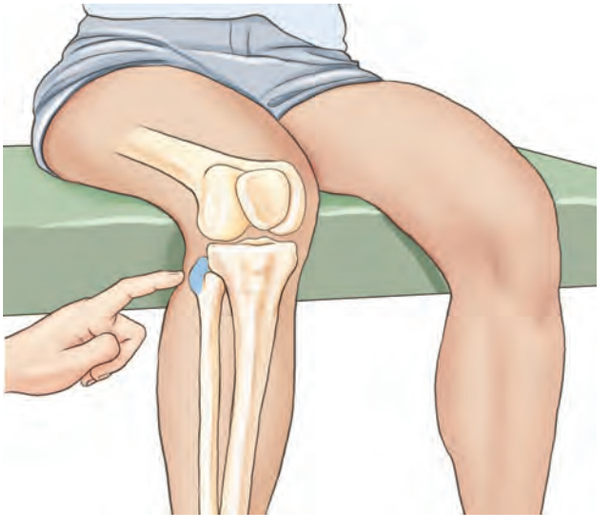

FIGURE 5-57 Head of the fibula: As you continue palpating along the superior margin of the lateral condyle of the tibia, you will reach the head of the fibula. The **head of the fibula** is the most proximal landmark of the fibula, is located on the posterolateral side of the knee, and can be palpated anteriorly, laterally, and posteriorly.

NOTE: The common fibular nerve is superficial near the head of the fibula; therefore care should be taken when palpating here.

ANTEROLATERAL VIEW

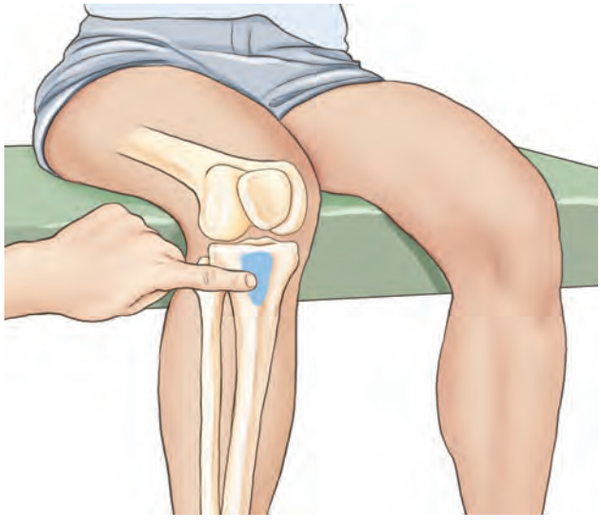

FIGURE 5-58 Tibial tuberosity: The **tibial tuberosity** is a prominent landmark located at the center of the proximal shaft of the anterior tibia, approximately 1 to 2 inches distal to the inferior margin of the patella. The quadriceps femoris muscle group attaches onto the tibial tuberosity.

ANTEROLATERAL VIEW

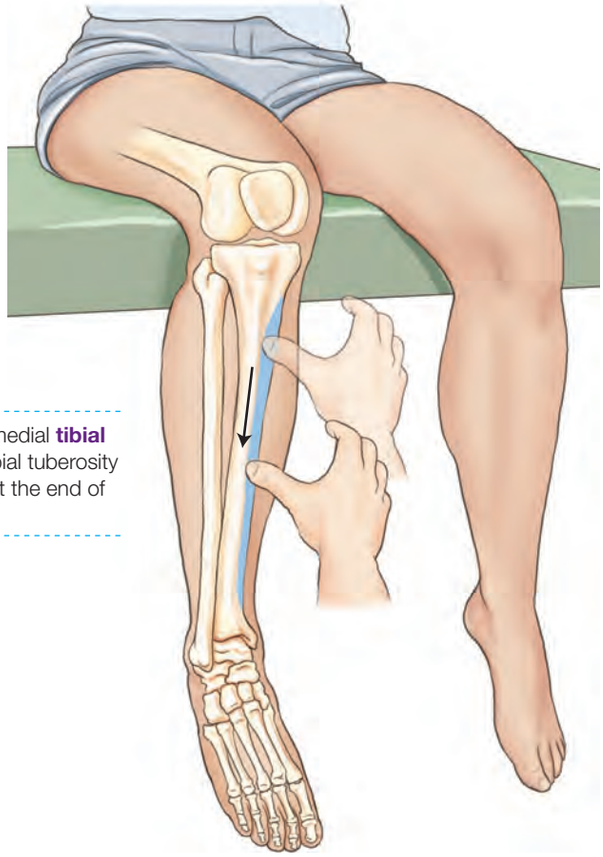

FIGURE 5-59 Tibial shaft: From the tibial tuberosity, the entire anteromedial **tibial shaft** is subcutaneous and easily palpable. Begin palpating at the tibial tuberosity and continue palpating distally until you reach the medial malleolus at the end of the anteromedial tibial shaft.

Right Lateral View of the Muscles of the Shoulder Girdle Region

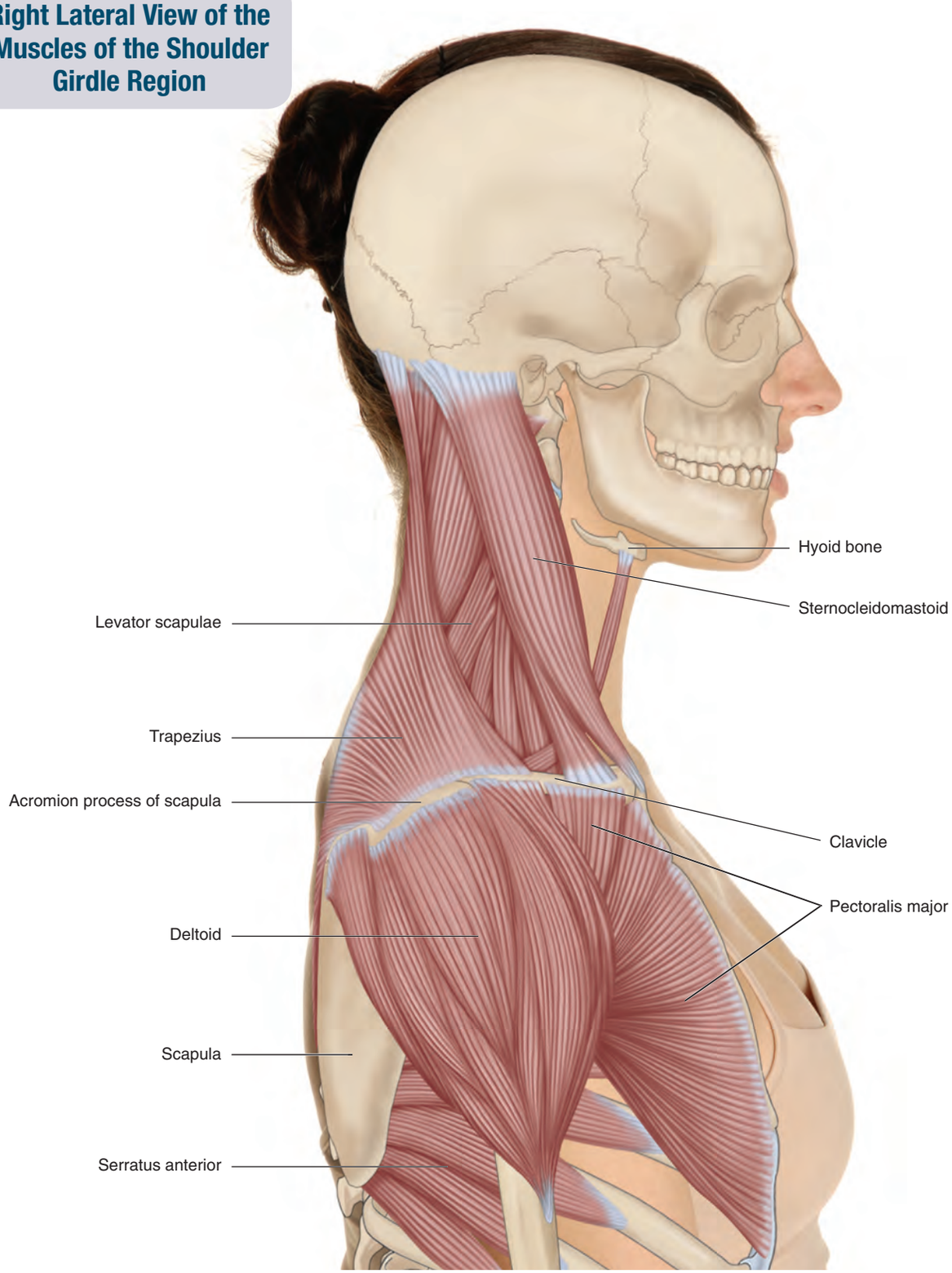

FIGURE 6-3

SHOULDER GIRDLE AND ARM

Trapezius

Pronunciation **tra-PEE-zee-us**

The trapezius is a broad flat superficial muscle that overlies the neck and middle and upper back. It is considered to have three parts: upper, middle, and lower. The trapezius is functionally important for neck and shoulder girdle motions (Figure 6-4).

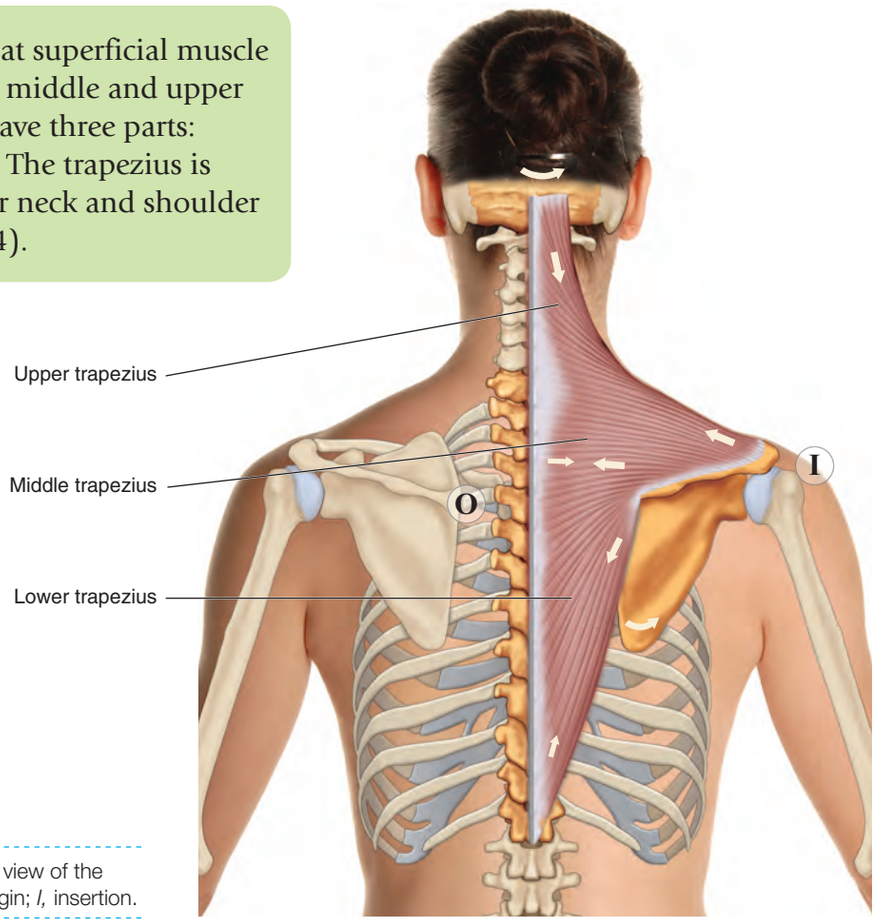

FIGURE 6-4 Posterior view of the right trapezius. *O,* Origin; *I,* insertion.

WHAT'S IN A NAME?

The name, *trapezius,* tells us that this muscle is shaped similar to a trapezoid (▱).

✻ **Derivation:**
trapezius: Gr. a little table (or trapezoid shape)

ATTACHMENTS

Origin (Proximal/Medial Attachment)

- External occipital protuberance, medial one third of the superior nuchal line of the occiput, nuchal ligament, and spinous processes of C7-T12

Insertion (Distal/Lateral Attachment)

- Lateral one third of the clavicle, acromion process, and spine of the scapula

ACTIONS

The trapezius moves the scapula at the scapulocostal joint and moves the head and neck at the spinal joints.

Upper Fibers

- Elevate the scapula.
- Upwardly rotate the scapula.
- Retract the scapula.
- Extend the head and neck.
- Laterally flex the head and neck.
- Contralaterally rotate the head and neck.

Middle Fibers

- Retract the scapula.

Lower Fibers

- Depress the scapula.
- Upwardly rotate the scapula.

STABILIZATION

1. Stabilizes the shoulder girdle.
2. Stabilizes the head, neck, and trunk.

Stabilization Function Note: The upper trapezius is extremely important for stabilizing the shoulder girdle when the arm is abducted and/or flexed at the glenohumeral joint.

INNERVATION

- Spinal accessory nerve (cranial nerve [CN] XI)

PALPATION

1. Ask the client to lie prone with the arm resting on the table at the side of the body.
2. To palpate the lower and middle trapezius, place the palpating finger pads just lateral to the lower and middle thoracic spine. Then ask the client to abduct the arm to 90 degrees with the elbow joint extended; and slightly retract the scapula by pinching the shoulder blade toward the spine. Adding gentle resistance to the client's arm abduction with your support hand is usually helpful. Palpate perpendicular to the fibers between the spine and scapula (Figure 6-5, *A*).
3. To palpate the upper trapezius, ask the client to extend the head slightly. Look for the engagement of the upper trapezius and palpate it in the neck up to its occipital attachment (Figure 6-5, *B*).
4. Note that the upper trapezius is quite narrow; it only attaches to the medial one third of the superior nuchal line of the occiput. The semispinalis capitis muscle, the largest muscle in the neck, is deep to the upper trapezius.

TREATMENT CONSIDERATIONS

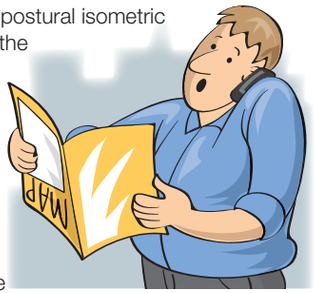

- Many positions require postural isometric contraction overuse of the upper trapezius. These positions include holding the head inclined anteriorly when working in front of the body using a hand-held electronic device such as a smart phone, carrying a purse or bag on the shoulder (regardless of the weight), crimping a telephone between the ear and the shoulder, holding the arm outward in an abducted position, or carrying a heavy weight in the hand.
- Weakness of the trapezius can contribute to the condition of rounded/slumped shoulders.
- Because the greater occipital nerve pierces through the upper trapezius, when the upper trapezius is tight, it can compress this nerve, which causes a tension headache. This condition is also known as *greater occipital neuralgia*.

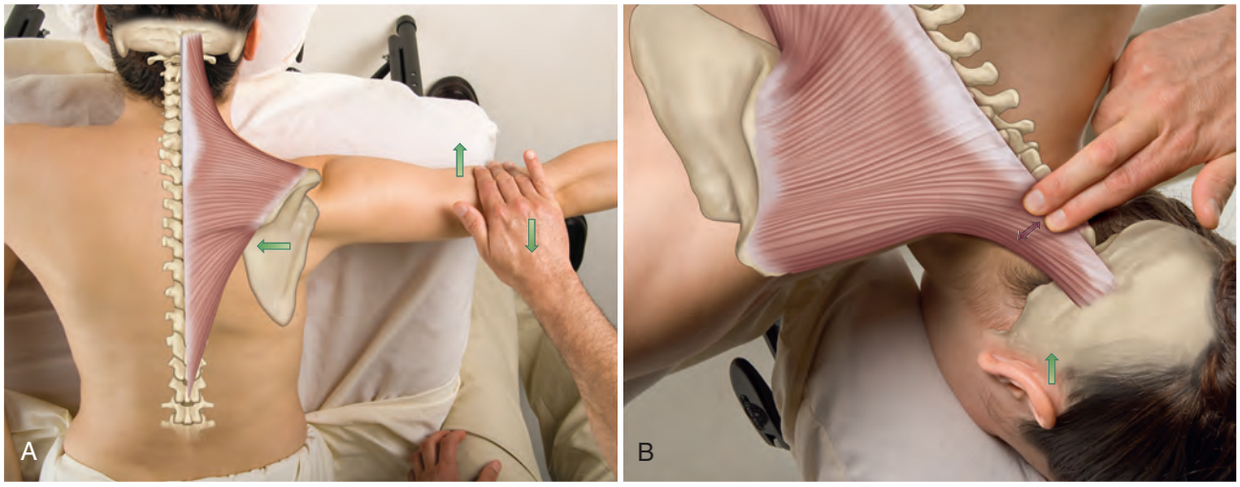

FIGURE 6-5 ***A,*** To engage the entire right trapezius, the client abducts the arm at the glenohumeral joint (resistance can be added as shown) and slightly retracts the scapula at the scapulocostal joint. ***B,*** Palpation of the upper trapezius is shown. Asking the client to extend the head and neck slightly at the spinal joints facilitates palpation of the upper trapezius. For all three parts of the trapezius, palpate by strumming perpendicular to the fiber direction as shown.

SHOULDER GIRDLE AND ARM: Pectoralis Group

Pectoralis Major; Pectoralis Minor

Pronunciation **PEK-to-ra-lis MAY-jor • PEK-to-ra-lis MY-nor**

The pectoralis major and minor muscles are located in the pectoral (chest) region. The pectoralis major is considered to have two heads, a clavicular head and a sternocostal head; it is superficial, attaches to the arm, and creates the anterior axillary fold of tissue that borders the axilla (the armpit) anteriorly. The pectoralis minor is deep to the pectoralis major and attaches to the scapula (Figure 6-12).

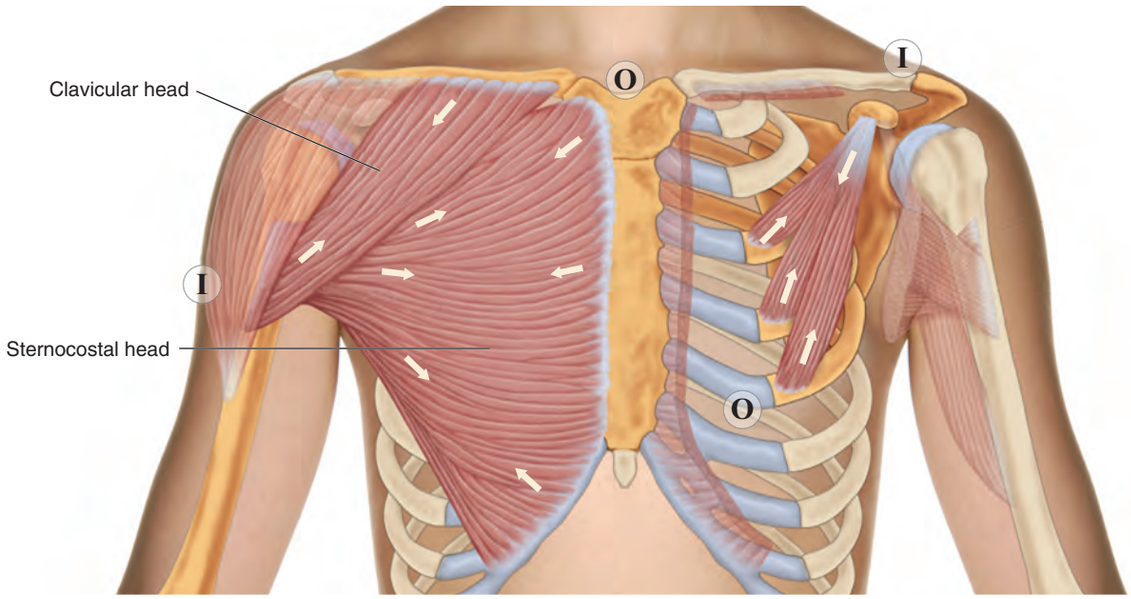

FIGURE 6-12 Anterior view of the right pectoralis major and left pectoralis minor. The deltoid has been ghosted in on the right side. The coracobrachialis and cut pectoralis major have been ghosted in on the left side. *O,* Origin; *I,* insertion.

WHAT'S IN A NAME?

The name, *pectoralis,* tells us that these muscles are located in the pectoral (chest) region. Major and minor tell us that the pectoralis major is larger than the pectoralis minor.

❊ **Derivation:**
pectoralis: L. refers to the chest
major: L. larger
minor: L. smaller

ATTACHMENTS

Pectoralis Major

Origin (Proximal/Medial Attachment)

- Medial clavicle, sternum, and the costal cartilages of ribs one through seven

Insertion (Distal/Lateral Attachment)

- Lateral lip of the bicipital groove of the humerus

Pectoralis Minor

Origin (Proximal/Anterior Attachment)

- Ribs three through five

Insertion (Distal/Posterior Attachment)

- Coracoid process of the scapula

ACTIONS

Pectoralis Major

The pectoralis major moves the arm at the glenohumeral joint and moves the scapula at the scapulocostal joint.

- Adducts the arm (entire muscle).
- Medially rotates the arm (entire muscle).
- Flexes the arm (clavicular fibers).
- Extends the arm (sternocostal fibers).
- Protracts the scapula.

PECTORALIS MAJOR STABILIZATION

1. Stabilizes the glenohumeral joint.
2. Stabilizes the shoulder girdle.

Pectoralis Minor

The pectoralis minor moves the scapula at the scapulocostal joint and moves the ribs at the sternocostal and costospinal joints.

- Protracts the scapula.
- Depresses the scapula.
- Downwardly rotates the scapula.
- Elevates ribs three through five.

PECTORALIS MINOR STABILIZATION

1. Stabilizes the shoulder girdle.
2. Stabilizes ribs three through five.

INNERVATION

- Medial and lateral pectoral nerves

Note: The medial and lateral pectoral nerves innervate both the pectoralis major and minor.

PALPATION

Pectoralis Major

1. Client is supine with the arm resting at the side.
2. To palpate the sternocostal head, place palpating finger pads over the lower aspect of the anterior axillary fold of tissue. Ask the client to adduct the arm against resistance and feel for the contraction of the sternocostal head; palpate toward its proximal (medial) attachment (Figure 6-13, *A*).
3. To palpate the clavicular head, place palpating finger pads just inferior to the medial clavicle. Ask the client to move the arm obliquely between flexion and adduction against resistance and feel for the contraction of the clavicular head; palpate toward the distal attachment (Figure 6-13, *B*)

Pectoralis Minor

1. Client is supine with the hand under the body in the small of the back or seated with the hand in the small of the back. Place palpating finger pads just inferior to the coracoid process of the scapula.
2. Ask the client to press the hand and forearm down against the table if supine or move the hand posteriorly away from the small of the back if seated; feel for the contraction of the pectoralis minor through the pectoralis major (Figure 6-14, *A-B*).
3. Palpate to the rib attachments, strumming perpendicular to the fibers.

FIGURE 6-13 Palpation of the right pectoralis major. ***A,*** Palpation of the sternocostal head is demonstrated as the client performs adduction against resistance. ***B,*** Palpation of the clavicular head is demonstrated as the client performs an oblique plane motion of flexion and adduction against resistance.

Turn page to more.

TREATMENT CONSIDERATIONS



- If the pectoralis muscles are tight, they pull the shoulder girdle into protraction, causing the postural condition known as *rounded/slumped shoulders*.
- The brachial plexus of nerves and the subclavian artery and vein are sandwiched between the pectoralis minor and the rib cage. Therefore this region is a common entrapment site for these nerves and blood vessels. If the pectoralis minor is tight, then these vessels and nerves may be compressed and the condition is called *pectoralis minor syndrome*—one of the three types of *thoracic outlet syndrome*.
- A tight pectoralis minor, by rounding the shoulders, can also contribute to the clavicle dropping toward the first rib, causing compression of the brachial plexus of nerves and subclavian artery and vein. This occurrence is called *costoclavicular syndrome*—one of the three types of *thoracic outlet syndrome*.

FIGURE 6-14 ***A,*** Palpation of the right pectoralis minor is perpendicular to the fibers as the client presses the hand and forearm down against the table. ***B,*** Having the client seated is the easiest position for palpating the pectoralis minor, because the client can comfortably place the hand in the small of the back and move it posteriorly when asked to do so.

SPINE AND RIB CAGE

Quadratus Lumborum (QL)

Pronunciation **kwod-RAY-tus lum-BOR-um**

The quadratus lumborum (QL) is a square-shaped muscle in the low back that attaches to the spine, rib cage, and pelvis (Figure 8-15). It is deep to the erector spinae.

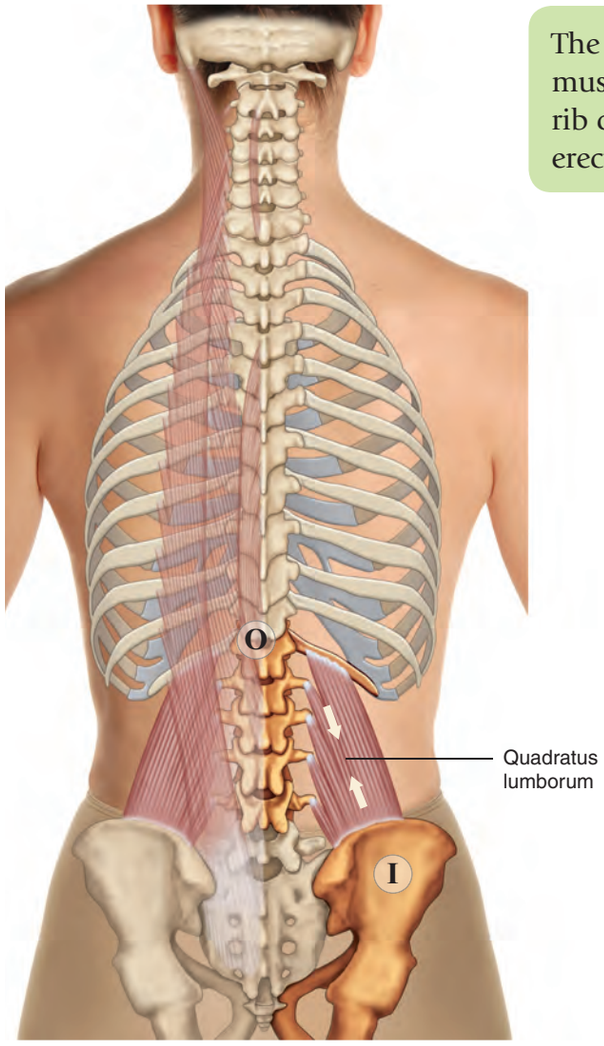

FIGURE 8-15 Posterior view of the quadratus lumborum bilaterally. The erector spinae group has been ghosted in on the left side. *O,* Origin; *I,* insertion.

WHAT'S IN A NAME?

The name, *quadratus lumborum,* tells us that this muscle is shaped somewhat like a square and is located in the lumbar (i.e., lower back) region.

❊ **Derivation:**
quadratus: L. squared
lumborum: L. loin (low back)

ATTACHMENTS

Origin (Proximal Attachment)

- Twelfth rib and the transverse processes of L1-L4

Insertion (Distal Attachment)

- Posterior iliac crest

ACTIONS

The quadratus lumborum moves the trunk at the spinal joints, the pelvis at the lumbosacral joint, and the twelfth rib at the costospinal joint.

- Elevates the same-side pelvis.
- Anteriorly tilts the pelvis and extends the lower lumbar spine relative to the upper lumbar spine.
- Extends the trunk.
- Laterally flexes the trunk.
- Depresses the twelfth rib.

STABILIZATION

Stabilizes the pelvis, lumbar spinal joints, and twelfth rib.

INNERVATION

- Lumbar plexus

PALPATION

1. The client is prone. Place your palpating finger pads just lateral to the lateral border of the erector spinae in the lumbar region.

Note: Placing the fingers of other hand on the palpating fingers for extra support can be helpful.

FIGURE 8-16 ***A,*** Palpation of the right quadratus lumborum as the client elevates the right side of the pelvis. The outline of the right erector spinae group has been ghosted in. ***B,*** Once the quadratus lumborum has been located, palpate in all three directions toward the rib, transverse process, and iliac attachments.

2. First locate the lateral border of the erector spinae musculature. (To do so, ask the client to raise the head and upper trunk from the table.) Then place your palpating finger just lateral to the lateral border of the erector spinae.
3. Direct palpating pressure medially, deep to the erector spinae musculature, and feel for the quadratus lumborum.
4. To engage the quadratus lumborum, ask the client to elevate the pelvis on that side at the lumbosacral joint and feel for its contraction (Figure 8-16, *A*).

   Note: The pelvis should move along the plane of the table toward the head; in other words, the pelvis should not lift up in the air, away from the table.

5. Once located, palpate medially and superiorly toward the twelfth rib, medially and inferiorly toward the iliac crest, and directly medially toward the transverse processes of the lumbar spine (Figure 8-16, *B*).

TREATMENT CONSIDERATIONS

- When working on the quadratus lumborum, you can position the client either prone, supine, or side lying. However, because much of this muscle is deep to the massive erector spinae musculature, it must be accessed with palpatory pressure from lateral to medial (i.e., come in from the side).
- Keep in mind that the quadratus lumborum is not the only muscle in the lateral lumbar region and should not be blamed for all the pain in this area. The nearby erector spinae musculature is also likely to develop tension and pain.
- If the quadratus lumborum is tight, it can pull up on the pelvic bone, causing the iliac crest on that side to elevate. This elevation can be seen during the postural assessment examination.
- The quadratus lumborum is important for stabilizing the twelfth rib when the diaphragm contracts during inspiration. Stabilization increases the efficiency of the diaphragm during breathing.

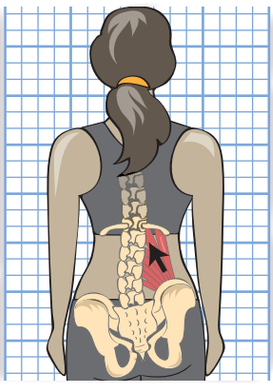

Anterior Views of the Muscles of the Hip Joint—Superficial and Intermediate Views

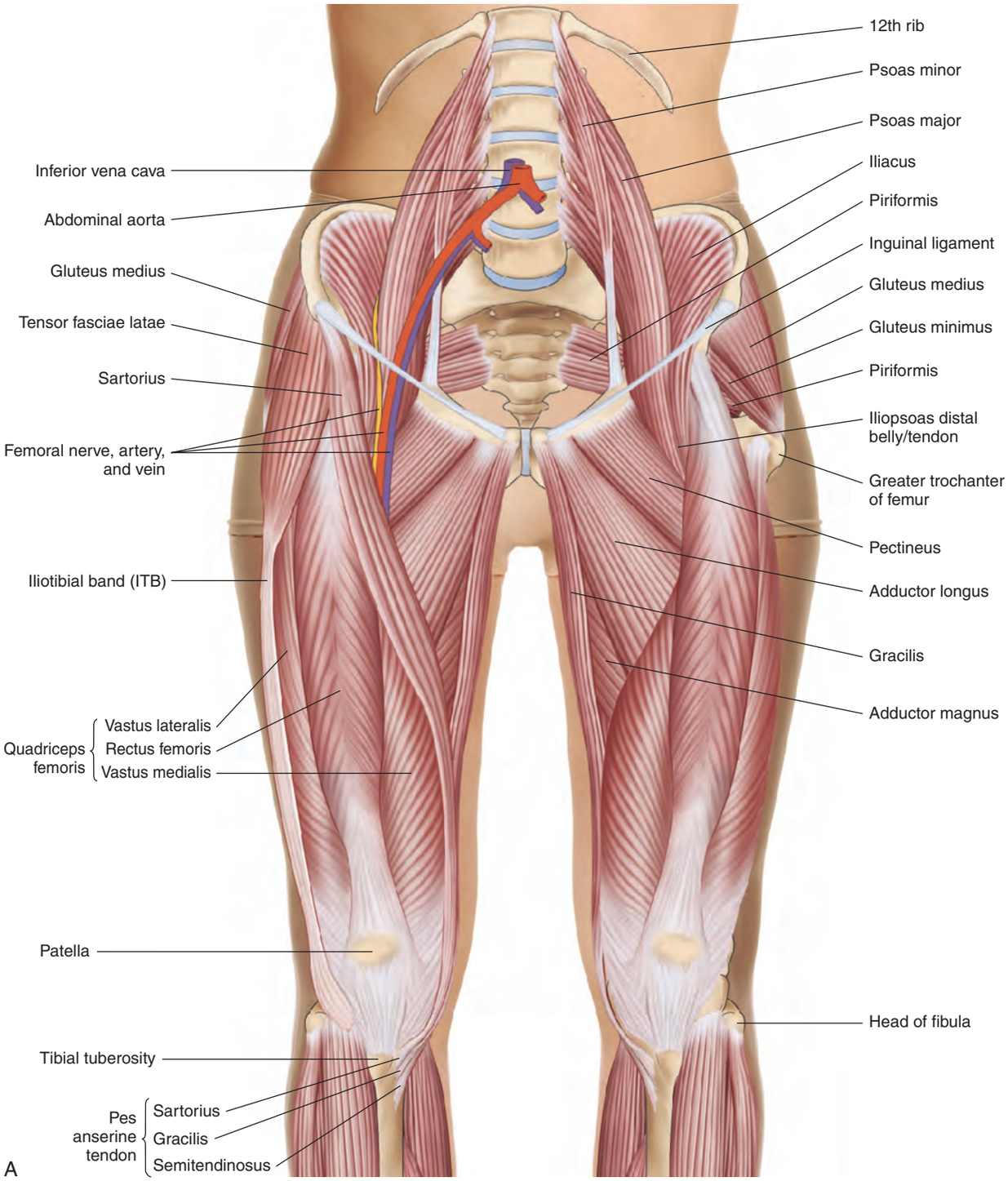

FIGURE 10-1 Anterior views of the muscles of the hip joint. ***A,*** Superficial view on the right and an intermediate view on the left.

Continued

Posterior Views of the Muscles of the Hip Joint—Superficial and Intermediate Views

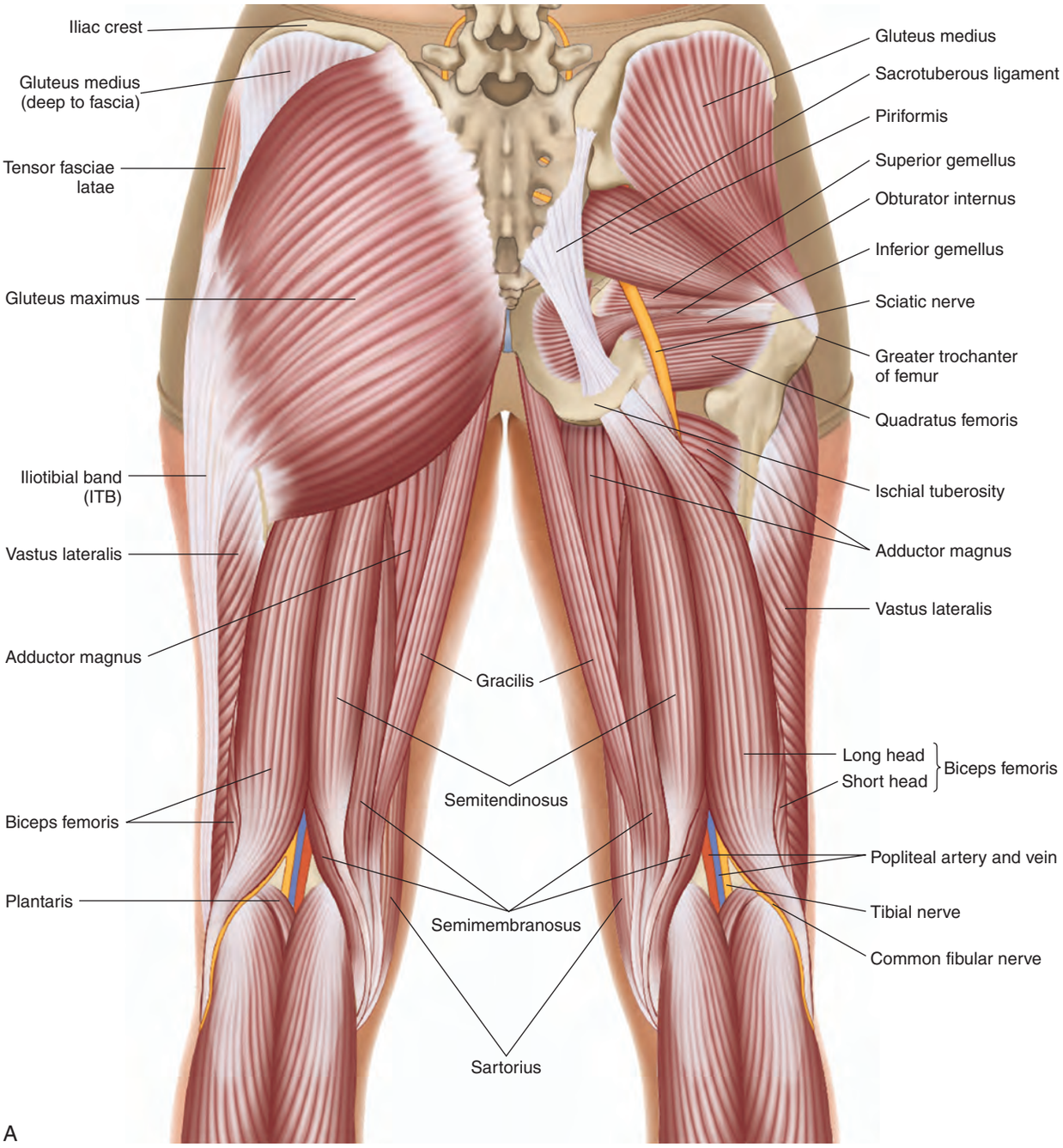

FIGURE 10-2 Posterior views of the muscles of the hip joint. ***A,*** Superficial view on the left and an intermediate view on the right.

Continued

MUSCLES OF THE PELVIS AND THIGH: Gluteal Group

Gluteus Maximus; Gluteus Medius; Gluteus Minimus

Pronunciation GLOO-tee-us MAX-i-mus • GLOO-tee-us MEED-ee-us • GLOO-tee-us MIN-i-mus

The gluteal group is composed of three muscles, the gluteus maximus, gluteus medius, and gluteus minimus. The gluteus maximus is the largest muscle in the human body and forms the contour of the buttock. It is superficial and covers much of the gluteus medius. The gluteus medius is deep to the gluteus maximus posteriorly and deep to the tensor fasciae latae anteriorly, but it is superficial laterally. It covers most all of the gluteus minimus. The gluteus minimus is the deepest and smallest of the group (Figure 10-4).

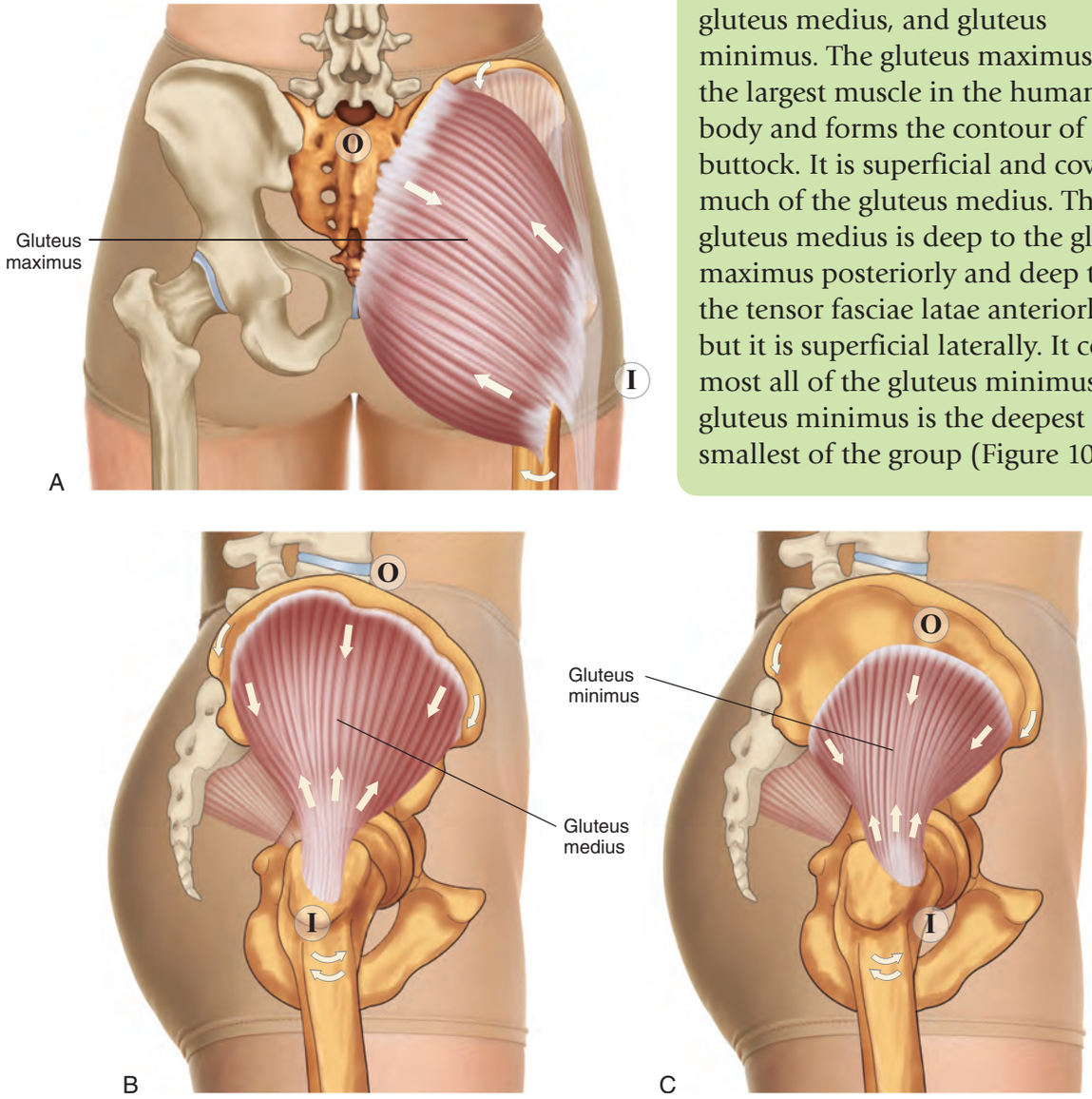

FIGURE 10-4 ***A,*** Posterior view of the right gluteus maximus. The tensor fasciae latae, fascia over the gluteus medius, and iliotibial band have been ghosted in. ***B,*** Lateral view of the right gluteus medius. The piriformis has been ghosted in. ***C,*** Lateral view of the right gluteus minimus. The piriformis has been ghosted in. *O,* Origin; *I,* insertion.

WHAT'S IN A NAME?

The name, *gluteus maximus,* tells us that this muscle is located in the gluteal (buttock) region and is larger than the gluteus medius and gluteus minimus.

The name, *gluteus medius,* tells us that this muscle is located in the gluteal region and is smaller than the gluteus maximus and larger than the gluteus minimus.

The name, *gluteus minimus,* tells us that this muscle is located in the gluteal region and is smaller than the gluteus maximus and gluteus medius.

❊ **Derivation:**
gluteus: Gr. buttocks
maximus: L. greatest
medius: L. middle
minimus: L. least

ATTACHMENTS

Gluteus Maximus

Origin (Proximal Attachment)

- Posterior iliac crest, posterolateral sacrum, and coccyx

Insertion (Distal Attachment)

- Iliotibial band (ITB) and the gluteal tuberosity of the femur

Gluteus Medius and Minimus

Origin (Proximal Attachment)

- External ilium

Insertion (Distal Attachment)

- Greater trochanter of the femur

ACTIONS

All of the actions listed for the gluteal muscles occur at the hip joint. The standard actions (insertion/distal attachment moving toward origin/proximal attachment) move the thigh at the hip joint; the reverse actions (origin/proximal attachment moving toward insertion/distal attachment) move the pelvis at the hip joint.

Gluteus Maximus

- Extends the thigh.
- Laterally rotates the thigh.
- Abducts the thigh (upper fibers only).
- Adducts the thigh (lower fibers only).
- Posteriorly tilts the pelvis.
- Contralaterally rotates the pelvis.

Gluteus Medius and Minimus

- Abduct the thigh.
- Extend the thigh (posterior fibers only).
- Flex the thigh (anterior fibers only).
- Laterally rotate the thigh (posterior fibers only).
- Medially rotate the thigh (anterior fibers only).
- Depress the same-side pelvis.
- Posteriorly tilt the pelvis.
- Anteriorly tilt the pelvis.
- Contralaterally rotate the pelvis.

STABILIZATION

Stabilizes the thigh and pelvis at the hip joint.

INNERVATION

- Inferior gluteal nerve (gluteus maximus)
- Superior gluteal nerve (gluteus medius and minimus)

PALPATION

Gluteus Maximus

1. The client is prone. Place your palpating finger pads lateral to the sacrum. Place your resistance hand on the distal posterior thigh (if resistance is needed).
2. Ask the client to laterally rotate the thigh at the hip joint and then extend the laterally rotated thigh. Feel for the contraction of the gluteus maximus (Figure 10-5). Resistance can be added, if necessary.
3. With the muscle contracted, strum perpendicular to the fibers to discern the borders of the muscle.
4. Continue palpating the gluteus maximus laterally and inferiorly (distally) to its insertion (distal attachments) by strumming perpendicular to its fibers.

Turn page to more.

Gluteus Medius and Minimus

1. The client is side lying. Place your palpating finger pads just distal to the middle of the iliac crest, between the iliac crest and the greater trochanter of the femur. Place your resistance hand on the lateral surface of the distal thigh (if resistance is needed).
2. Palpating just distal to the middle of the iliac crest, ask the client to abduct the thigh at the hip joint. Feel for the contraction of the middle fibers of the gluteus medius (Figure 10-6, *A*). If desired, resistance can be added to the client's thigh abduction with the resistance hand.
3. Strum perpendicular to the fibers, palpating the middle fibers of the gluteus medius distally toward the greater trochanter.
4. To palpate the anterior fibers, place your palpating hand immediately distal and posterior to the anterior superior iliac spine (ASIS), and ask the client to gently flex and medially rotate the thigh at the hip joint. Feel for the contraction of the anterior fibers of the gluteus medius (Figure 10-6, *B*). Discerning the anterior fibers from the more superficial tensor fasciae latae is difficult.
5. To palpate the posterior fibers, place your palpating hand over the posterior portion of the gluteus medius, and ask the client to gently extend and laterally rotate the thigh at the hip joint. Feel for the contraction of the posterior fibers of the gluteus medius (Figure 10-6, *C*). Discerning the posterior fibers from the more superficial gluteus maximus is difficult.
6. Palpating and discerning the gluteus minimus deep to the gluteus medius is difficult. The gluteus minimus is thickest anteriorly. To palpate the gluteus minimus, follow the same procedure as for the gluteus medius, and try to palpate deeper for the gluteus minimus.

FIGURE 10-5 Palpation of the right gluteus maximus as the client extends and laterally rotates the thigh at the hip joint against resistance.

FIGURE 10-6 Side-lying palpation of the right gluteus medius. ***A,*** Palpation of the middle fibers of the right gluteus medius immediately distal to the middle of the iliac crest as the client attempts to abduct the thigh at the hip joint against resistance. ***B,*** Palpation of the anterior fibers of the gluteus medius as the client abducts and medially rotates the thigh. ***C,*** Palpation of the posterior fibers of the gluteus medius as the client abducts and laterally rotates the thigh.

TREATMENT CONSIDERATIONS

- Thinking of the gluteus maximus as the *speed skater's muscle* can be helpful. The gluteus maximus is powerful in extending, abducting, and laterally rotating the thigh at the hip joint, which are all actions that are necessary when speed skating.
- Usually a thick layer of fascia, called the *gluteal fascia* or the gluteal aponeurosis, overlies the gluteus medius muscle.
- Lateral rotation of the thigh at the hip joint by the gluteal muscles acts to prevent medial rotation of the thigh and entire lower extremity, including the talus at the subtalar joint. This lateral rotation can stabilize the subtalar joint and prevent excessive pronation (dropping of the arch) of the foot.

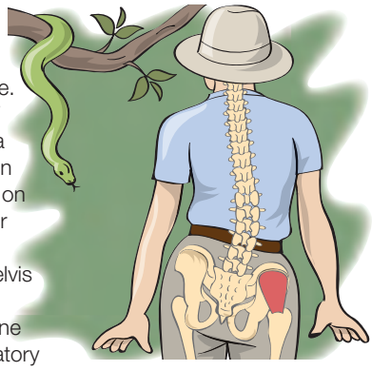

- When the gluteus medius is tight, it pulls on and depresses the pelvis toward the thigh on that side. This results in a *functional short leg* (as opposed to a *structural short leg* wherein the femur and/or the tibia on one side is actually shorter than on the other side). Further, depressing the pelvis on one side creates an unlevel sacrum for the spine to sit on, and a compensatory scoliosis must occur to return the head to a level position.
- When one foot is lifted off the floor, the pelvis should fall to that side because it is now unsupported. However, the gluteus medius and minimus on the support-limb (opposite) side, which contract and create a force of same-side depression of the pelvis, prevent the pelvis from falling to that side. Therefore the pelvis remains level. With every step a person takes, contraction of the gluteus medius on the support side occurs. You can easily feel this when walking or even walking in place.
- The gluteus medius and minimus contract to create a force of same-side pelvic depression when weight is simply shifted to one foot. Therefore the habitual practice of standing with all or most of the body weight on one side tends to cause the gluteus medius and minimus on that side to become overused and tight.
- The gluteus medius can be thought of as the "deltoid of the hip joint" because it performs all the same actions to the thigh at the hip joint as the deltoid does to the arm at the glenohumeral joint.

MUSCLES OF THE PELVIS AND THIGH: Iliopsoas

Iliacus; Psoas Major

Pronunciation **I-lee-o-SO-as • i-lee-AK-us • SO-as MAY-jor**

The iliopsoas is composed of two muscles: the iliacus and psoas major. These two muscles have distinct origins (proximal attachments), but their distal bellies blend, and they have a common insertion (distal attachment) on the femur. The psoas major's belly lies deep in the posterior abdominal wall against the lumbar spine. The iliacus lies deep against the anterior (internal) surface of the pelvic bone. However, their distal belly is superficial immediately distal to the inguinal ligament (Figure 10-15).

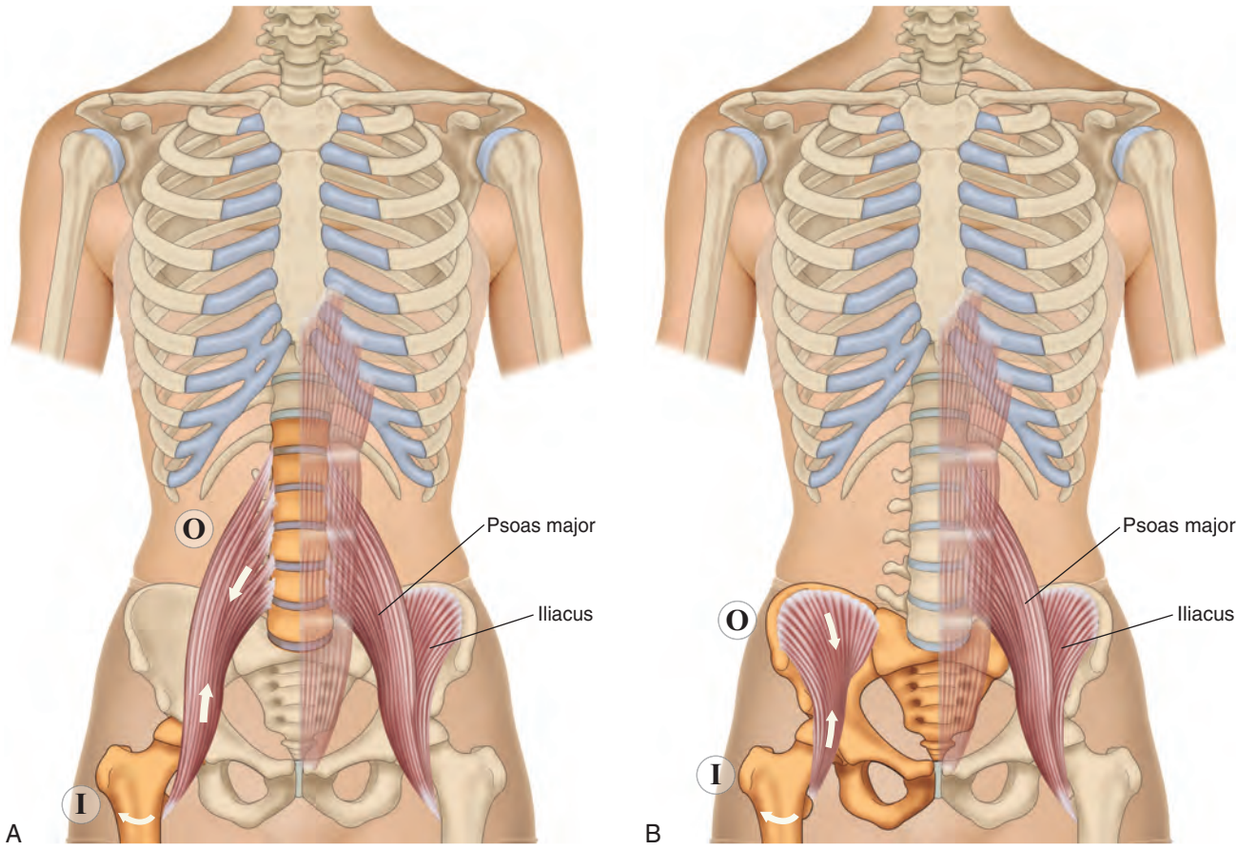

FIGURE 10-15 ***A,*** Anterior view of the psoas major bilaterally. The left iliacus has been drawn in, and the rectus abdominis has been ghosted in. ***B,*** Anterior view of the iliacus bilaterally. The left psoas major has been drawn in, and the rectus abdominis has been ghosted in. *O,* Origin; *I,* insertion.

WHAT'S IN A NAME?

The name, *iliacus,* tells us that this muscle attaches onto the ilium.

The name, *psoas major,* tells us that this muscle is located in the loin (low back) area and is larger than the psoas minor.

Derivation:
iliacus: L. refers to the ilium
psoas: Gr. loin (low back)
major: L. larger

ATTACHMENTS

Iliacus

Origin (Proximal Attachment)

- Internal ilium

Insertion (Distal Attachment)

- Lesser trochanter of the femur

Psoas Major

Origin (Proximal Attachment)

- Anterolateral lumbar spine

Insertion (Distal Attachment)

- Lesser trochanter of the femur

ACTIONS

Both the iliacus and psoas major move the thigh and pelvis at the hip joint. The psoas major also moves the trunk at the lumbar spinal joints.

Iliacus

- Flexes the thigh.
- Laterally rotates the thigh.
- Anteriorly tilts the pelvis.

Psoas Major

- Flexes the thigh.
- Laterally rotates the thigh.
- Anteriorly tilts the pelvis.
- Flexes the trunk.

STABILIZATION

1. Both the iliacus and psoas major stabilize the thigh and pelvis at the hip joint.
2. The psoas major also stabilizes the lumbar spinal joints.

INNERVATION

- Femoral nerve (iliacus)
- Lumbar plexus (psoas major)

PALPATION

1. The client is seated with the trunk slightly flexed. Place your palpating finger pads anterolaterally on the client's abdominal wall, approximately halfway between the umbilicus and the anterior superior iliac spine (ASIS); ensure placement is lateral to the lateral border of the rectus abdominis.
2. Place the finger pads of your other hand over the fingers of your palpating hand to increase the strength and stability of the palpating fingers (Figure 10-16, *A*).
3. Ask the client to take in a deep but relaxed breath. As the client exhales, slowly (but firmly) sink in toward the belly of the psoas major by pressing diagonally in toward the spine. You may need to repeat this procedure two to three times before arriving at the psoas major.
4. To confirm that you are on the psoas major, ask the client to gently flex the thigh at the hip joint by lifting the foot slightly off the floor. Feel for the contraction of the psoas major.
5. Strum perpendicularly across the fibers to feel for the width of the muscle. Continue palpating the psoas major toward its superior vertebral attachment and inferiorly as far as possible within the abdominopelvic cavity.

   Note: The psoas major can also be palpated with the client supine with a roll under the knees (see Figure 10-16, *B*).

6. To palpate the iliacus, curl your fingers around the iliac crest with your finger pads oriented toward the internal surface of the ilium. Feel for the iliacus (Figure 10-17). To engage the iliacus, ask the client to flex the thigh at the hip joint by lifting the foot slightly off the floor.
7. The distal belly of the iliopsoas is also palpable in the proximal anterior thigh between the pectineus and the sartorius (Figure 10-18).

Turn page to more.

FIGURE 10-16 ***A,*** Palpation of the right psoas major as the client gently flexes the thigh at the hip joint by lifting her foot up slightly from the floor. ***B,*** The psoas major can also be palpated with the client supine or side lying. The disadvantage of the supine palpation position is that when the client flexes the thigh at the hip joint, the muscles of the abdominal wall may contract to stabilize the pelvis. This action can interfere with feeling the psoas major, located deep to these muscles. This action may also occur to some degree with the side-lying palpation position.

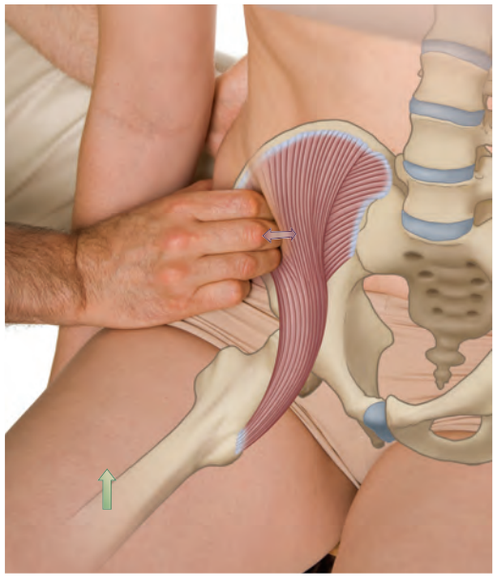

FIGURE 10-17 The right iliacus is palpated by curling the fingers around the iliac crest so that the finger pads are oriented against the muscle.

FIGURE 10-18 Palpation of the distal belly and tendon of the psoas major in the proximal thigh (immediately distal to the inguinal ligament) as the client flexes (curls) the trunk at the spinal joints against gravity. The sartorius has been ghosted in.

TREATMENT CONSIDERATIONS

- With regard to posture, a chronically tight iliopsoas anteriorly tilts the pelvis, causing the lumbar curve to increase (*hyperlordosis*, also known as *swayback*). Straight-legged sit-ups tend to strengthen the iliopsoas disproportionately in comparison to the anterior abdominal wall muscles. To avoid this, curl-ups are recommended, wherein the hip and knee joints are flexed and the trunk "curls" up (flexes) approximately 30 degrees.

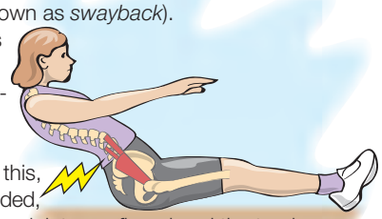

- The roots of the lumbar plexus of nerves enter and pierce the psoas major muscle. Therefore a tight psoas major may entrap these nerves.
- Tenderloin (also known as *filet mignon*) is the psoas major of a cow.
- **You must be careful with palpation of the distal belly of the iliopsoas in the proximal thigh because the femoral nerve, artery, and vein lie over the iliopsoas and pectineus in the femoral triangle here.**

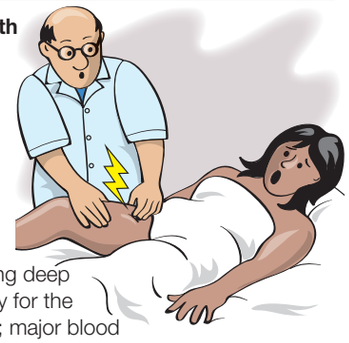

- Be careful when palpating deep into the abdominal cavity for the belly of the psoas major; major blood vessels (aorta and iliac arteries) are located nearby. If you feel a pulse under your fingers, move your palpating fingers off the artery.
- The psoas major is usually cited as a flexor of the lumbar spine because it crosses anteriorly to the axis of motion for the lumbar vertebrae. However, if the client has a hyperlordotic lumbar spine (swayback), the relationship of the psoas major's fibers relative to the joints can change such that it crosses posteriorly and is now an extensor.

Appendix: Stretching Atlas

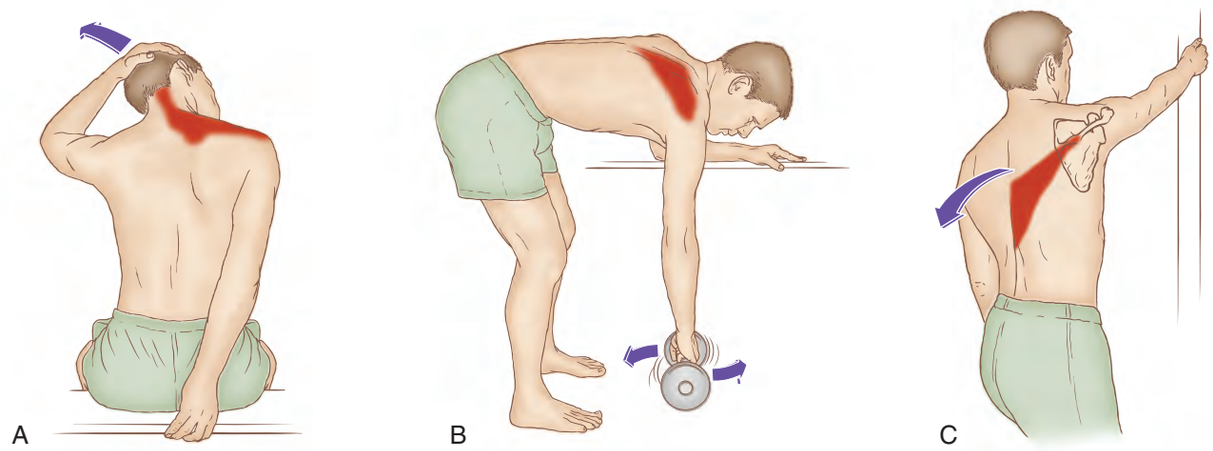

FIGURE 1 Trapezius.

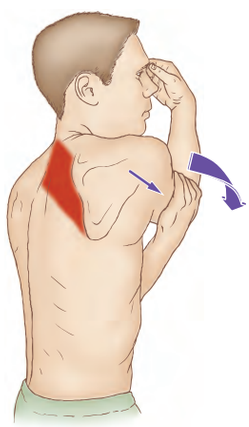

FIGURE 2 Rhomboids.

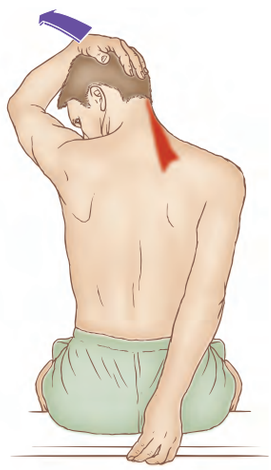

FIGURE 3 Levator scapulae.

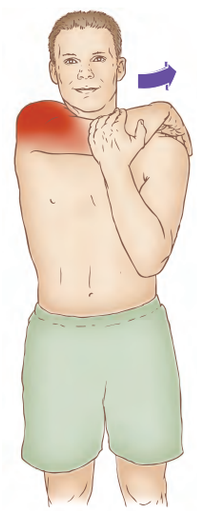

FIGURE 4 Posterior deltoid.

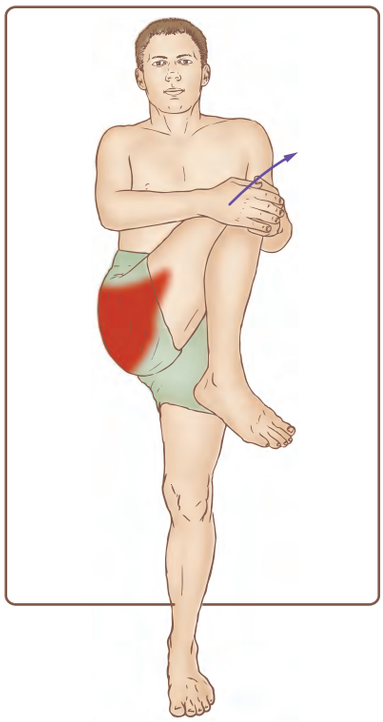

FIGURE 54 Gluteus maximus. **Note:** If the client experiences a pinching sensation in the groin with this stretch, it is helpful to either first stretch the hip flexors (especially the sartorius and iliopsoas) before doing this stretch or to first laterally rotate and abduct the thigh at the hip joint to untwist and slacken the hip joint capsule before performing the stretch.

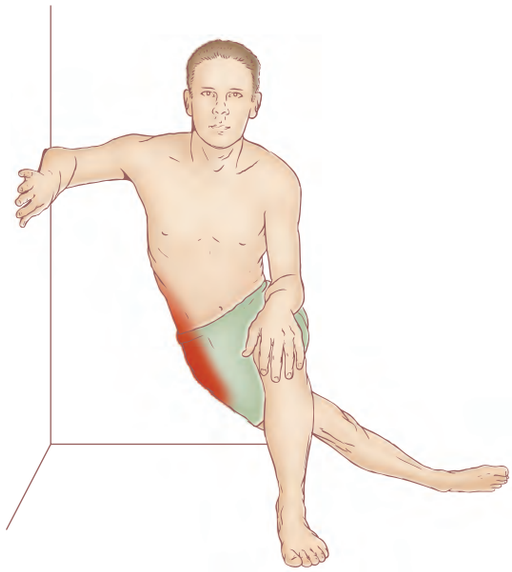

FIGURE 55 Gluteus medius and tensor fasciae latae. **Note:** It is important to avoid placing too much weight on the ankle joint of the foot in back.

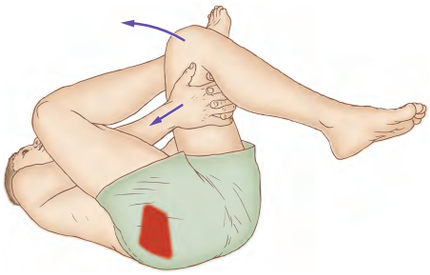

FIGURE 56 Piriformis.

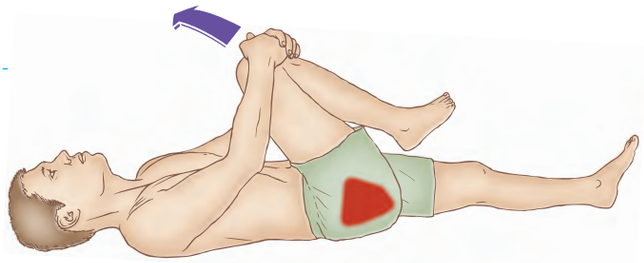

FIGURE 57 Quadratus femoris. **Note:** If the client experiences a pinching sensation in the groin with this stretch, it is helpful to first stretch the hip flexors (especially the sartorius and illiopsoas) before stretching or to first laterally rotate and abduct the thigh at the hip joint to untwist and slacken the hip joint capsule before doing this stretch.

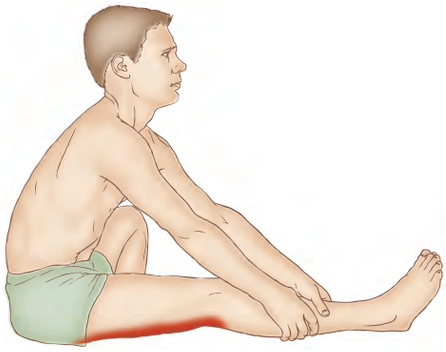

FIGURE 58 Hamstring group. **Note:** The spine does not need to bend in this stretch.