Thoracic Outlet Syndrome

by Joe Muscolino

THORACIC OUTLET SYNDROME

The upper thoracic region is where neurovascular structures exit into or 'outlet' into the upper extremity. These structures are the brachial nerve plexus, the subclavian artery and the subclavian vein. Thoracic outlet syndrome (TOS) is the name given to the group of pathologic conditions in which compression of these neurovascular structures occurs (Figure 1).

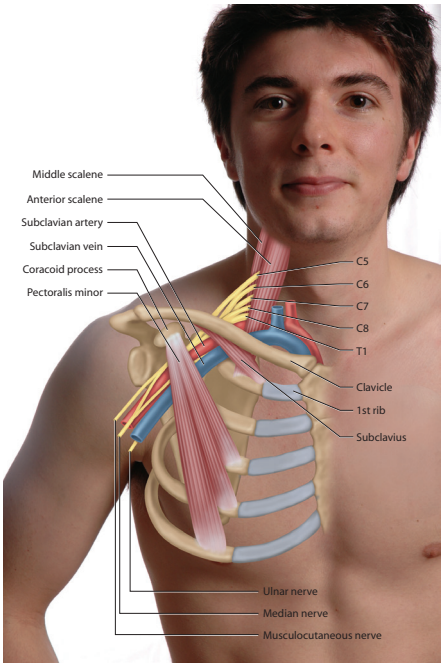

▲ **Figure 1:** The three entrapment sites of thoracic outlet syndrome (TOS) are between the anterior and middle scalenes, between the first rib and clavicle, and between the pectoralis minor and rib cage.

There are three major types of TOS, named after the region where the compression occurs:

1. anterior scalene syndrome, which occurs between the anterior and middle scalenes
2. costoclavicular syndrome, which occurs between the first rib and the clavicle
3. pectoralis minor syndrome, which occurs between pectoralis minor and the rib cage.

These conditions are grouped together as TOS because they are all neurovascular compression conditions that can cause the same signs and symptoms into the upper extremity. Further, the same pathologic mechanisms often underlie more than one type of TOS so it is common for a client to present with two or all three forms of TOS.

Anterior scalene syndrome

The brachial nerve plexus and the subclavian artery run between the anterior and middle scalenes. If the scalenes become tight, compression of these structures can occur. Scalenes are commonly tight due to whiplash injuries in which the head and neck are forcefully thrown posteriorly or contralaterally, straining or overstretching them, and triggering a muscle spindle reflex that causes them to spasm. Scalenes can also tighten due to adaptive shortening in response to chronic postural influences, such as typically occurs with a hypolordotic neck. Additionally, they can tighten due to their overuse as assistant muscles of inspiration, presenting in clients who have laboured breathing from chronic respiratory diseases such as asthma, emphysema or chronic bronchitis.

Costoclavicular syndrome

The brachial nerve plexus, subclavian artery and subclavian vein run within the costoclavicular space between the first rib and the clavicle. If this space decreases, these neurovascular structures can become impinged. The costoclavicular space will narrow if the clavicle and first rib approximate each other. This can occur in three ways:

1. The clavicle depresses toward/against the first rib. This can be observed in the common postural condition of rounding and slumping of the shoulders. A tight subclavius can also cause this to occur.
2. The first rib elevates toward/against the clavicle. This often occurs in clients who have laboured breathing. Tight anterior and middle scalenes and subclavius can also cause this to occur.
3. The clavicle depresses and the first rib elevates.

Pectoralis minor syndrome

The brachial nerve plexus, subclavian artery and subclavian vein run between the pectoralis minor and the rib cage. If the pectoralis minor becomes tight, these structures can be impinged. Pectoralis minor syndrome is the most common form of TOS because the pectoralis minor is so often tight. The common postural distortion pattern of rounded shoulders (protracted scapula/clavicle) causes shortening of the pectoralis minor. Then, due to adaptive shortening, the pectoralis minor increases its tone to tighten at this shortened length. However, tightening of the pectoralis minor due to it being overstretched is also fairly common. This occurs if the arm is abducted and then suddenly and forcefully stretched posteriorly behind the body. Also, like the scalenes, the pectoralis minor is often recruited as an accessory muscle of inspiration and may tighten in clients with laboured breathing.

Cervical rib TOS

There is a fourth type of TOS that is often referred to as "true TOS". This condition is caused by the presence of a small, genetically anomalous cervical rib that is attached by fibrous tissue to the transverse process of the seventh cervical vertebra.

The presence of this rib can cause compression of the brachial nerve plexus and/or the subclavian artery.

SIGNS AND SYMPTOMS

If we understand that the pathomechanics of TOS is compression of neurovascular structures, the signs and symptoms can be extrapolated. Compression of the sensory portion of a nerve can cause tingling, numbness, decreased sensation (hypoesthesia), increased sensation (hyperesthesia) or pain. Compression of the motor portion of a nerve can cause weakness or twitching of the associated musculature.

The brachial plexus is composed of five major nerves: the median, radial, ulnar, musculocutaneous, and axillary nerves. Figure 2 shows their sensory innervation distribution in the hand.

Because all three forms of TOS can cause compression of the brachial nerve plexus, all of the aforementioned sensory and motor signs and symptoms can occur. These signs and symptoms could occur anywhere within the upper extremity because the brachial plexus innervates the entire upper extremity (the word brachial refers to the arm).

If the subclavian artery is compressed, the strength of the pulse in the upper extremity will decrease (but the speed of the pulse will not be affected). Most commonly, the radial pulse on the radial side of the distal forearm is the pulse that is assessed to determine whether there is compression. If the subclavian vein is compressed, venous drainage would be compromised, causing swelling in the upper extremity.

Signs and symptoms of neurologic compression with TOS are more common than signs and symptoms of subclavian artery or vein compression. Specifically, tingling and numbness in the hand are the most commonly found symptoms of TOS. However, understanding the mechanics of subclavian artery compression is important when assessing TOS.

ASSESSMENT

Knowing how to assess TOS is also an extension of our understanding of the underlying pathomechanics of the condition. Even though the effects of neural compression are the most common presenting complaints of TOS, it is the effect of arterial compression that is primarily used to assess this condition.

A different assessment test is used for each of the three forms of TOS. Common to all of them is that the client is moved into a position that increases the neurovascular entrapment of that condition while the strength of the radial pulse is assessed. If the strength of the radial pulse diminishes (showing that the subclavian artery is compressed), then it can be reasoned that any neurologic signs and symptoms that the client is experiencing are coming from the same entrapment site. In this manner, the specific form of TOS can be assessed.

Adson's test (for anterior scalene syndrome)

The assessment test used for anterior scalene syndrome is called Adson's test. It is performed by feeling for the strength of the radial pulse while asking the client to rotate the head and neck to the same (ipsilateral) side, and then extend and laterally flex the head and neck to the opposite (contralateral) side (Figure 3). This position maximally stretches and pulls taut the anterior and middle scalenes on the side being assessed[1]. This may entrap the neurovascular structures as they pass between the two muscles.

The test is positive if the strength of the radial pulse diminishes. It is also positive if the client experiences an increase of neurologic symptoms into the upper extremity on that side.

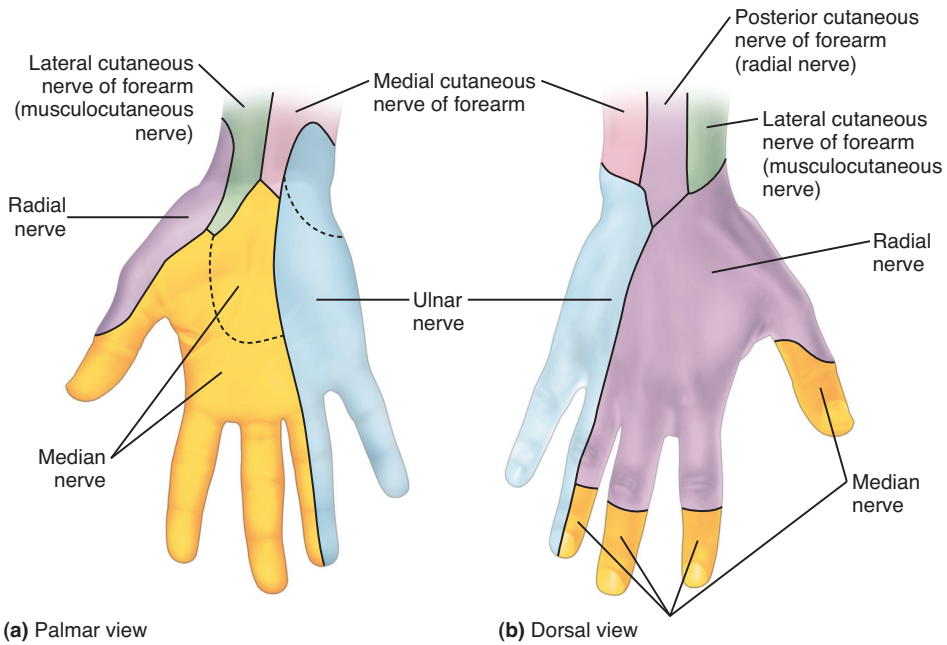

▲ **Figure 2:** Sensory innervation distribution of the hand.

▲ **Figure 3:** Adson's test for anterior scalene syndrome.

[1] Adson's test stretches/elongates the anterior and middle scalenes because the client is asked to perform the actions that are opposite to the actions of these muscles. The anterior and middle scalene flex and do same-side (ipsilateral) lateral flexion; the anterior scalene also does opposite-side (contralateral) rotation.

Adson's test will also likely show as positive if the client has TOS caused by a cervical rib.

Eden's test (for costoclavicular syndrome)

The assessment test used for costoclavicular syndrome is called Eden's test. It is performed by feeling for the strength of the radial pulse while asking the client to stick the chest out and pull the shoulder girdles back, as if standing in a military position of attention (not surprisingly, Eden's test is also known as the military brace test) (Figure 4).

▲ **Figure 4:** Eden's test for costoclavicular syndrome.

This position maximally approximates the clavicle and first rib, decreasing the costoclavicular space and possibly entrapping the neurovascular structures as they pass through this space.

Eden's test is positive if the strength of the radial pulse diminishes. It is also positive if the client experiences an increase of neurologic symptoms into the upper extremity on that side.

Wright's test (for pectoralis minor syndrome)

The assessment test used for pectoralis minor syndrome is called Wright's test. It is performed by feeling for the strength of the radial pulse while passively extending and abducting the client's arm at the glenohumeral joint (Figure 5). This position maximally stretches the pectoralis minor and entraps and compresses the neurovascular structures between the pectoralis minor and the rib cage.

Wright's test is positive if the strength of the radial pulse diminishes. It is also positive if the client experiences an increase of neurologic symptoms into the upper extremity on that side.

▲ **Figure 5:** Wright's test for pectoralis minor syndrome.

There is also an alternative version of Wright's test. It is performed by asking the client to abduct the arm at the glenohumeral joint and flex the forearm at the elbow joint. The forearm can be rested on the head (Figure 6). This tethers the neurovascular structures around the pectoralis minor. If the pectoralis minor is tight, compression will likely occur. The same criteria are used to determine a positive result.

Addendum to Adson's, Eden's and Wright's tests

To intensify the tests described above, ask the client to take in and hold a deep breath. This will increase the possible compression in each condition, specifically:

- it causes the anterior and middle scalenes to contract in an effort to lift their rib cage attachments, thereby intensifying Adson's test for anterior scalene syndrome
- it causes the rib cage to lift, approximating it toward the clavicle, thereby intensifying Eden's test for costoclavicular syndrome

▲ **Figure 6:** Alternative position for Wright's test for pectoralis minor syndrome.

- it causes the pectoralis minor to contract in an effort to lift its rib cage attachment, thereby intensifying Wright's test for pectoralis minor syndrome.

The advantage of adding this component is that it makes each test more sensitive, allowing a milder case of TOS to be detected. However, the disadvantage is that taking in and holding a breath can cloud the discernment of exactly which form of TOS is present (or which forms are present) because any one form of TOS can now possibly show positive to all three tests.

Brachial plexus tension test

If any of the three forms of TOS are found to be present, it is possible to determine which brachial plexus nerve is being impinged. This can be accomplished in two ways.

One approach is to note what region of the client's upper extremity is symptomatic and compare it to a dermatomal map of innervation (see Figure 2). Another approach is to perform the brachial plexus tension test (BPTT). The BPTT is actually a series of three tests, each one designed to assess one of the three major nerves of the brachial plexus that innervate the hand: the median, radial and ulnar nerves.

The concept behind each of the three BPTTs is to place the client into a position that maximally stretches that nerve. The BPTT is considered to be positive if the client experiences increased sensory symptoms in the upper extremity dermatomal distribution region of that nerve.

In all three versions of the BPTT, the client's shoulder girdle is depressed, the arm is abducted at the glenohumeral joint and the neck is laterally flexed to the opposite side, because all three of these nerves travel in the axillary region and side of the neck and would therefore be stretched by these joint motions.

• Median nerve test

The elbow, wrist and finger joints are extended because the median nerve crosses them anteriorly. The forearm is supinated because the median nerve enters the forearm on the medial side. (Figure 7a).

▲ **Figure 7a:** Brachial plexus tension test. Median nerve test.

• Radial nerve test

The elbow joint is extended because the radial nerve crosses it anteriorly. The wrist joint is flexed and ulnar deviated because the radial nerve crosses it on the posterior and radial side. The finger joints are flexed because the radial nerve crosses them on the posterior side. The forearm is pronated because the radial nerve enters the forearm from the lateral side (Figure 7b).



▲ **Figure 7b:** Brachial plexus tension test. Radial nerve test.

• Ulnar nerve test

The elbow joint is flexed because the ulnar nerve crosses it posteriorly. The wrist joint is extended and radially deviated because the ulnar nerve crosses it on the anterior and ulnar side. The finger joints are extended because the ulnar nerve crosses them on the anterior side. The forearm is supinated because the ulnar nerve enters the forearm from the medial side (Figure 7c).

▲ **Figure 7c:** Brachial plexus tension test. Ulnar nerve test.

DIFFERENTIAL ASSESSMENT

TOS can cause neurologic sensory and/or motor symptoms anywhere in the upper extremity so any condition that can do this must be differentially assessed. These conditions include carpal tunnel syndrome, pronator teres syndrome and space occupying lesions in the neck (pathologic disc and bone spurs) that compress the spinal nerves that contribute to brachial plexus nerves (C5-T1 spinal nerves). Muscular trigger points can also refer pain into the upper extremity.

Further, because TOS can compress the subclavian artery and/or vein, vascular conditions should also be differentially assessed by the client's physician. These conditions include Raynaud's disease, diabetes mellitus and vitamin B12 deficiency.

It is critically important that, even if positive findings are found for any one of these conditions, you continue to assess for all of the rest. It is not uncommon for a client to have contributions from more than one underlying pathologic condition.

MANUAL TREATMENT

Manual treatment for TOS is usually very effective. The need to address the client's posture is common to all three types of TOS. Rounded shoulder posture is especially relevant to costoclavicular and pectoralis minor syndromes; forward head posture is especially relevant to anterior scalene syndrome. However, it is extremely common for these two postural distortion patterns to occur together, so addressing both of them for all three forms of TOS is a good idea.

The approach for rounded shoulder posture is to relax and lengthen the client's shoulder girdle protraction and glenohumeral joint medial rotation musculature, and to have the client strengthen the shoulder girdle retraction and glenohumeral joint lateral rotation musculature. The approach for forward head posture is to have the client relax head protraction musculature and strengthen head retraction musculature.

Beyond general postural work, specific work is required for each of the forms of TOS.

Treatment protocols for anterior scalene syndrome

For anterior scalene syndrome, focus needs to be primarily on the anterior and middle scalenes. A good protocol to follow is to apply moist heat to the scalenes, massage and then stretch them. Moist heat can be applied for approximately 5-10 minutes. Massage can be done with both longitudinal strokes and then cross-fibre strokes (Figure 8).

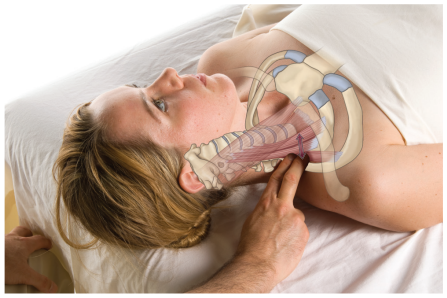

▲ **Figure 8:** Longitudinal and cross-fibre strokes to the anterior and middle scalenes.

To access the transverse process attachments of the scalenes, it is helpful to relax and slacken the sternocleidomastoid (SCM). This is accomplished by passively moving the client into lateral flexion on the side you are working. It is now possible to slip your finger pads deep to the SCM and find the scalenes' transverse process attachments (Figure 9a).

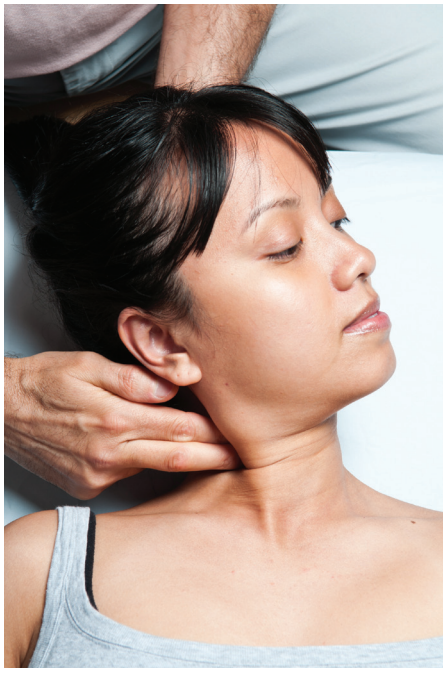

▲ **Figure 9a:** Massaging the scalenes' transverse process attachments deep to the sternocleidomastoid.

To access the rib attachments of the scalenes, it can be helpful to slightly passively flex the client's head and neck to slacken the anterior tissues and then reach deep to the clavicle with your finger pads oriented posteriorly (Figure 9b). Feel for the first rib attachments of the anterior and middle scalenes.

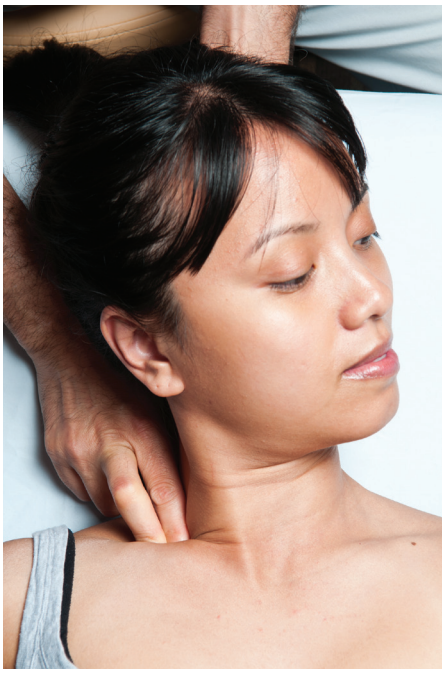

▲ **Figure 9b:** Massaging the scalenes' rib attachments deep to the clavicle.

If possible, try to locate the second rib attachment of the posterior scalene. Stretching the scalenes is shown in Figure 10.

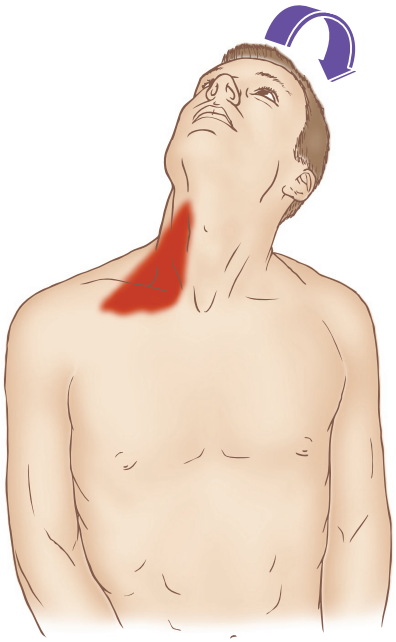

▲ **Figure 10:** Stretching the right scalenes.

When working the scalenes, it is important to be aware of the presence of the neurovascular structures running between the anterior and middle scalenes. When stretching the scalenes, caution must be exercised because it requires the client's neck to be extended beyond anatomic position.

Because tight deep neck flexors might also hold the neck in a shortened position of flexion, causing a hypolordotic cervical spine, it is advisable to also work the longus colli and longus capitis (Figure 11).

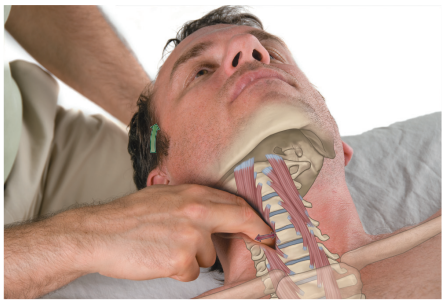

▲ **Figure 11:** Massaging the longus colli and longus capitis.

Treatment protocols for costoclavicular syndrome

For costoclavicular syndrome, the goal is to open the space between the clavicle and first rib. After placing moist heat on the region for approximately five to ten minutes, begin by working within the costoclavicular space itself (Figure 12).

▲ **Figure 12:** Massaging the soft tissues of the costoclavicular space between the first rib and clavicle.

The subclavius muscle is located here and, when tight, can decrease the space by pulling the clavicle and first rib toward each other. In addition to the subclavius, the entire costoclavicular space should be worked in case fascial adhesions are present.

The tissues of the costoclavicular space should now be stretched by passively bringing the client's arm back into extension and up into abduction.

This stretch is easiest to perform with the client seated or standing (Figure 13). It can be done with the supine client if the client is lying at the side of the table.

Finally, any other muscles that can either elevate the first rib into the clavicle or depress the clavicle into the first rib should be worked. These include the scalenes, pectoralis minor and pectoralis major.

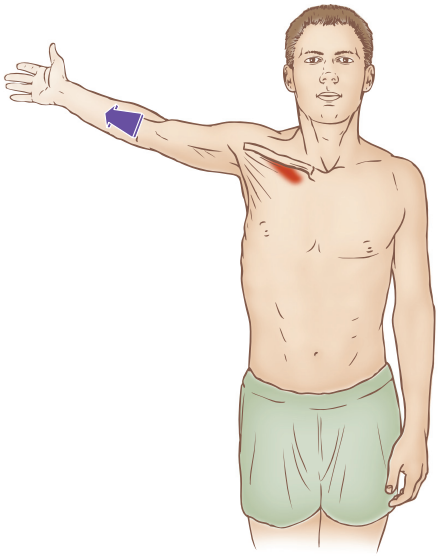

▲ **Figure 13:** Stretching the tissues of the costoclavicular space and pectoralis minor.

Treatment protocols for pectoralis minor syndrome

For pectoralis minor syndrome, the primary objective is to loosen the pectoralis minor. This can be accomplished by applying moist heat, and then massaging and stretching it. Massage strokes can be applied longitudinally along the fibres and then across the fibres (Figure 14).

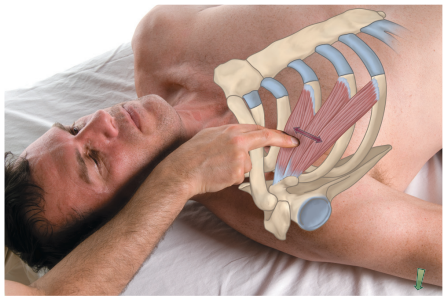

▲ **Figure 14:** Massaging the pectoralis minor - cross-fibre strokes.

If the overlying pectoralis major is tight then it should be slackened by positioning the client's arm slightly in flexion and adduction, so that the pectoralis minor can be worked through it.[2] Pin and stretch while working into the pectoralis minor is also very effective (Figure 15).

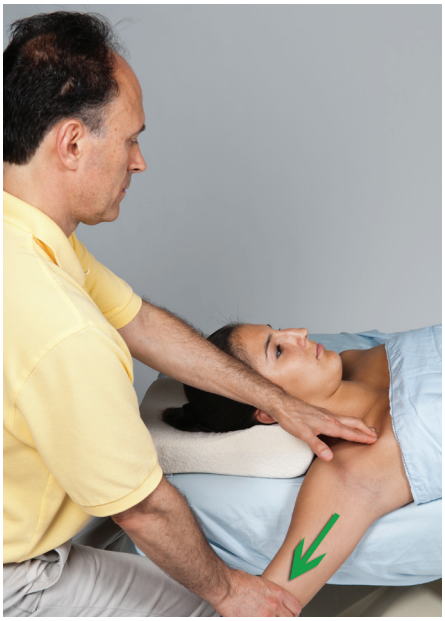

▲ **Figure 15:** Pin and stretch technique while working the pectoralis minor.

Agonist contract stretching technique is especially effective and easy to apply to the pectoralis minor when the client is seated. After working the pectoralis minor, it is recommended to work the entirety of the pectoralis major.

Summary of Manual Treatment Protocol for TOS

1. Loosen shoulder girdle protraction and glenohumeral joint medial rotation musculature; and recommend strengthening of shoulder girdle retraction and glenohumeral joint lateral rotation musculature
2. Apply moist heat, massage and stretching
3. For anterior scalene syndrome: work the anterior and middle scalenes
4. For costoclavicular syndrome: work the subclavius and fascial tissues of the costoclavicular space
5. For pectoralis minor syndrome: work the pectoralis minor

PRECAUTIONS/CONTRAINDICATIONS

When working on a client with TOS, it is important to avoid placing excessive pressure directly on the neurovascular structures. However, it may be impossible to completely avoid exerting pressure on them given their proximity to the muscles being worked, so care should be exercised. This is especially true when working the scalenes because the brachial nerve plexus and the subclavian artery are superficial and vulnerable in this region. If you feel a pulse, you are on the subclavian artery. Simply move your finger pads slightly off it and continue working. However, it is difficult to feel if you are on the brachial nerve plexus. If the client feels a sudden shooting pain down the upper extremity, you are most likely on the nerve plexus. Again, simply adjust your location to relieve pressure on the nerve and continue working.

Trigger points in the scalenes may also refer pain or other sensations into the upper extremity but this will not usually be a sudden shooting pain.

Caution also needs to be exercised when stretching the scalenes because this places the client's head and neck into extension beyond anatomic position.

[2] It is often recommended to work the pectoralis minor by reaching in from the armpit and deep to the pectoralis major. This tends to be uncomfortable for the client and is usually not necessary unless the pectoralis major is extremely tight, thereby blocking the ability to penetrate through it to the pectoralis minor. If this approach is employed, caution should be used to avoid pressing too far laterally on the brachial plexus of nerves and subclavian artery and vein.

For some clients, especially elderly ones, this position can be very uncomfortable. Because the stretch involves rotation and extension, it is a good idea to first perform the vertebral artery competency test bilaterally (Figure 16).



▲ **Figure 16:** Position of vertebral artery competency test.

If the client experiences dizziness or lightheadedness in this position, extension of the head and neck are contraindicated, especially when coupled with rotation.

SELF-CARE FOR THE CLIENT

Because poor posture can be a significant contributor to TOS, self-care is an extremely important aspect of the treatment. The client should be advised to avoid offending postures (rounded shoulders and anterior head carriage) as much as possible. Applying moist heat and then stretching the pectoralis minor (shoulder girdle protractor musculature) and scalenes is helpful. Strengthening exercises for the shoulder girdle retractor, glenohumeral joint lateral rotator and head retraction musculature are also extremely important.

Figure credits:

Figures 1-4: Reprinted with kind permission of the massage therapy journal (mtj). Photography by Yanik Chauvin. **Figure 1:** Artwork by Frank Forney. **Figure 2:** Artwork by Lightbox Visuals, Giovanni Rimasti.

Figures 5-7: Reprinted with permission from Muscolino J: Treatment Techniques for the Manual Therapist: Neck. Baltimore, MD: Lippincott Williams & Wilkins. In press. Photography by Yanik Chauvin.

Figures 8 & 10-14: From Muscolino JE: The muscle and bone palpation manual, with trigger points, referral patterns, and stretching. St. Louis, 2009. Elsevier. Photography by Yanik Chauvin.

Figures 9, 15 & 16: Courtesy of Joseph E. Muscolino. Photography by Yanik Chauvin.

Joseph E. Muscolino has been a massage therapy educator for 25 years, and a chiropractor in private practice for 26 years. He is the author of The Muscle and Bone Palpation Manual, With Trigger Points, Referral Patterns, and Stretching; The Muscular System Manual, The Skeletal Muscles of the Human Body, 3ed; and Kinesiology, The Skeletal System and Muscle Function, 2ed; as well as the upcoming Treatment Techniques for the Manual Therapist: Neck. Joe's books are translated into seven foreign languages.

Joe also teaches continuing professional education workshops and will be visiting Australia again in March next year.

For more information, visit his website: www.learnmuscles.com