Thoracic Spine

The Silent Saboteur

By Joseph E. Muscolino, DC

There is a saying

that no posture is bad unless you get stuck in it. The problem is that people often *do* get stuck in bad postures. And this is especially true for the thoracic spine. Postural distortion of the thoracic spine, even when advanced, is often asymptomatic and, therefore, ignored by the client, but can be a major cause of other postural distortion and pain patterns in the body. In this way, the thoracic spine could be viewed as a silent saboteur of our health. The client may not even mention the thoracic region when describing her problem, but we need to always consider and assess the thoracic spine when evaluating our clients' health.

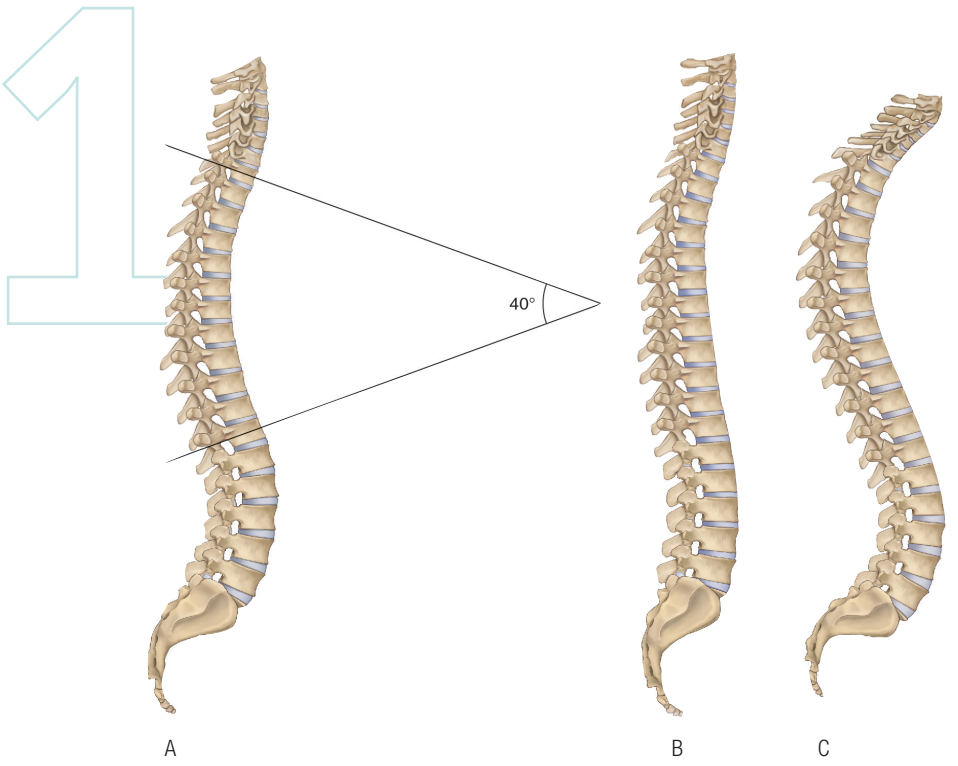

Healthy, natural kyphosis of the thoracic spine measures approximately 40 degrees (A). Hypokyphotic thoracic spine (B). Hyperkyphotic thoracic spine (C). *Reproduced with permission from Joseph E. Muscolino. Artwork by Giovanni Rimasti.*

ROUNDED BACK

A healthy thoracic spine should have a natural kyphotic curve that measures approximately 40 degrees (Image 1A). Although it is possible for this curve to be abnormally decreased (hypokyphotic, Image 1B), by far, the more common postural distortional pattern is for the thoracic spine to become hyperkyphotic (Image 1C). In lay terms, this is often described as *rounded back*.

A kyphotic curve is effectively a curve of flexion, so it makes sense that having a forward-flexed posture on a regular basis would lead to a hyperkyphotic, or hyperflexed, rounded thoracic posture. In addition, most everything we do in our modern world happens down in front of us—whether it is tending to a baby, cleaning a counter,

Postural distortion of the thoracic spine is rarely seen by the client himself, as it requires an assessment from the side to determine the actual degree of kyphotic curvature.

Working down in front of our body tends to promote a hyperflexed (hyperkyphotic) rounded thoracic spine. *Reproduced with permission from Joseph E. Muscolino. Artwork by Giovanni Rimasti.*

cutting vegetables, doing paperwork, or working with a laptop, tablet, or smartphone (Image 2). Working down in front of our body is not new, but with the tremendous proliferation of digital devices, the number of hours people spend hunched forward into flexion has increased exponentially. Indeed, it seems that hyperkyphosis of the thoracic spine is becoming more prevalent, and may now be the most common and problematic postural distortion pattern that manual and movement therapists encounter.

Like any postural distortion pattern, the longer we assume a rounded-back posture, the more the soft tissues adapt to the distortional pattern. With a rounded thoracic spine, the anterior pectoral musculature ends up shortening and tightening and the posterior spinal extensor musculature ends up lengthening and tightening in response (see "Locked-Short/Locked-Long" on page 77). Further, the anterior fascial/ligamentous tissue shortens and becomes taut and the posterior fascial/ligamentous tissue lengthens and weakens, thereby losing the tautness or tone to oppose the forward flexion. As the fascial tissue weakens, this increases the burden on the extensor musculature, which becomes further overwhelmed and dysfunctional in its attempt to prevent the forward progression.

As we move further into flexion, our center of weight moves anteriorly, increasing the leverage force of gravity, which furthers the force toward a forward-flexed posture. Additionally, staying stuck in a rounded-back posture also allows the buildup of fascial adhesions (often described as "fuzz" by educator Gil Hedley; watch Hedley's "The Fuzz Speech" at www.youtube.com/watch?v=_FtSP-tkSug) that further resist the body from moving back into extension. When this posture is extremely long-standing, for years or decades, even the bones remodel. The anterior aspects of the vertebral bodies narrow in height in response to the increased weight-bearing anterior compression force.

All these factors add up to a postural distortional pattern that, once set in motion, tends to become a vicious cycle that feeds on itself, steadily and progressively worsening. So, what begins as a seemingly innocuous voluntary forward posture that we pay little attention to, often transitions into a stubborn, rigid, dysfunctional pattern in which we become stuck. This pattern alters the health of the thoracic spine, and indeed, much of the rest of the upper body.

UPPER-CROSSED SYNDROME (UCS)

A rounded thoracic spine does not exist in isolation. Rather, it is usually part of a larger dysfunctional pattern that involves the neck, head, shoulder girdles, and arms. This larger pattern is often described as *upper-crossed syndrome* (UCS) and is so named because a cross (X) can be placed across the upper body. One arm of the cross represents overly facilitated (locked-short) musculature; the other arm represents overly inhibited (locked-long) musculature. The effect of the imbalanced asymmetrical pulls of the musculature results in the characteristic UCS posture, which involves hyperkyphosis of the thoracic spine, hypolordosis of the lower cervical spine, hyperlordosis of the upper cervical spine, forward-head carriage, protraction of the shoulder girdles, and medial/internal rotation of the arms at the glenohumeral joints (Image 3). Even though each of these postural distortions can be viewed as a separate entity, in reality, each one tends to increase the dysfunction of the others. However, the rounded-back thoracic hyperkyphosis is most fundamentally the root cause of the UCS pattern.

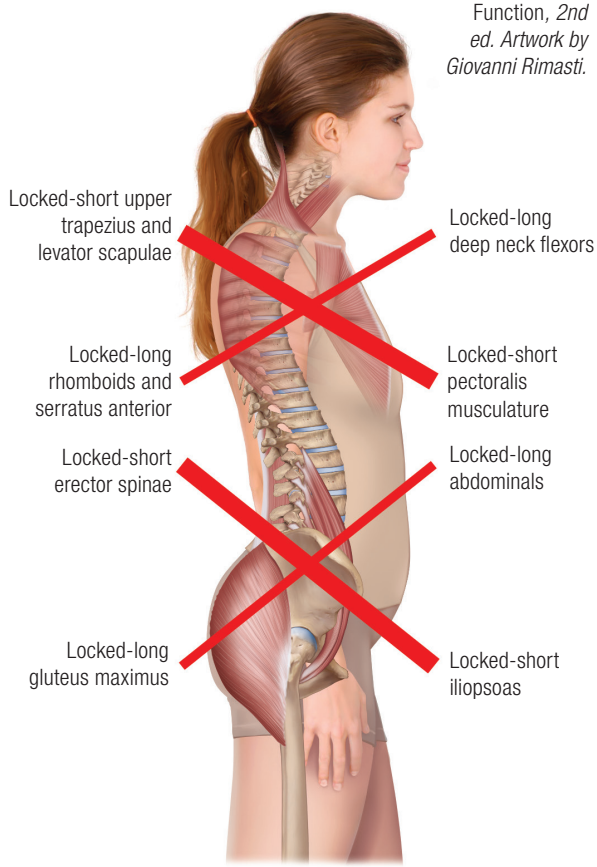

Upper-crossed syndrome. *Reproduced with permission from Joseph E. Muscolino.* Kinesiology: The Skeletal System and Muscle Function, *2nd ed. Artwork by Giovanni Rimasti.*

Locked-Short/ Locked-Long

When evaluating postural distortional patterns in the past, opposing muscle groups at a joint were classically described as being *tight* and *weak*. The assumption was that tight muscles were strong and weak muscles were loose, so the imbalance of bony posture at a joint was described as being caused by strong/ tight muscles on one side of the joint overpowering weak/ loose muscles on the other side. It is now understood this description does not fully and accurately describe the state of the relationship of these muscle groups to neuro-myo-fascio-skeletal posture and function.

Current wisdom favors the use of the terms ***overly facilitated*** and ***overly inhibited*** muscles. These terms incorporate the role of the nervous system in recruiting musculature to contract for postural patterns. Overly facilitated muscles are excessively favored by the nervous system to contract; and overly inhibited muscles are under-recruited by the nervous system to contract. The facilitated muscles end up overly concentrically contracted and short; the inhibited muscles are overpowered by the facilitated muscles and end up being pulled long. This results in the imbalanced pull across a joint and the resultant altered posture.

Certainly, the overly facilitated muscles can be described as tight. But it is not accurate to describe the inhibited muscles as loose. Ironically, because of the constant pull by the overly *facilitated* musculature, the overly *inhibited* musculature must increase its tone in an attempt to counter the effects, and ends up being, in a sense, tight and overly facilitated itself. Hence we have two opposing muscle groups: the tight and short facilitated muscles, *locked-short*; and the tight and long inhibited muscles, *locked-long*.

Because the length-tension relationship of muscle strength demonstrates that a muscle is strongest at resting length and weaker when it is longer or shorter, we can say both groups of muscles across the joint are overly weak. The inhibited musculature might be relatively weaker than the facilitated musculature, but in reality, both groups are weak. Effectively, we have tight and weak musculature on both sides of the joint. A classic example of this is the anterior pectoral musculature (locked-short; tight and weak) and the posterior shoulder girdle retractor and thoracic spinal extensor musculature (locked-long; tight and weak).

When applying this knowledge to manual therapy, we see that it is valuable to work the overly facilitated and the overly inhibited musculature because both groups are dysfunctionally tight and weak and are, therefore, likely to develop myofascial trigger points and fascial adhesions. This is important to recognize because there are many manual therapists who assert that only the locked-short musculature should be worked, likely because they feel that the opposing long musculature is already weak and would become even weaker if it were to be massaged and stretched. This is a fallacy. Manual therapy applied to any dysfunctional musculature, locked-short or locked-long, helps to restore the proper health and function of the musculature. Granted, the locked-short facilitated musculature should receive the lion's share of the work, but it is only when both groups are healthy and in balance that these postural distortional patterns can truly be improved.

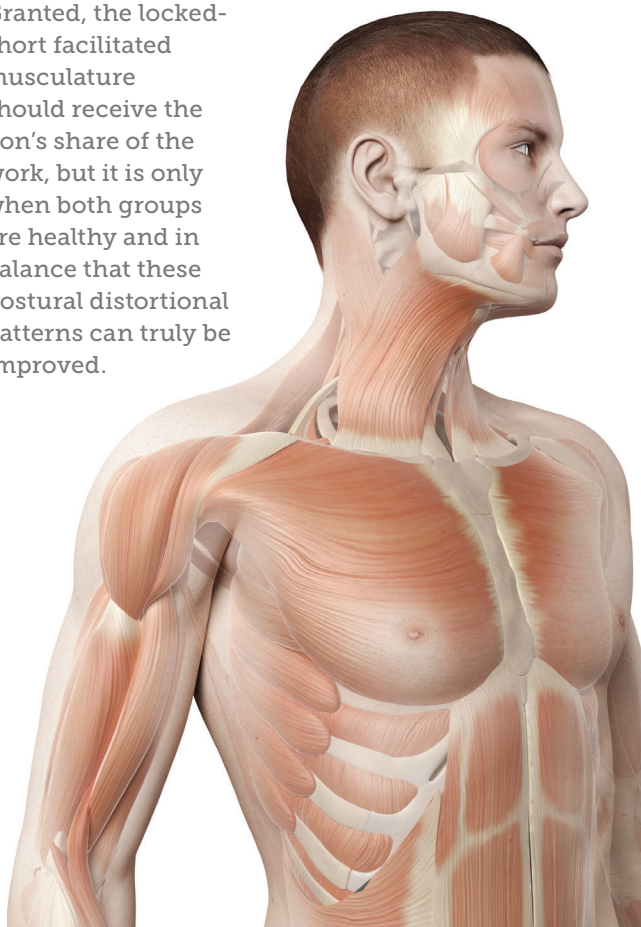

4

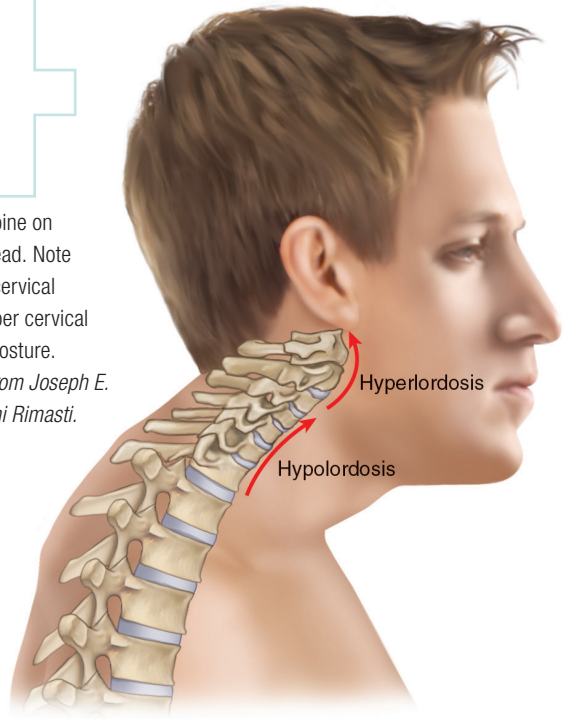

Effect of a rounded thoracic spine on the posture of the neck and head. Note the hypolordosis of the lower cervical spine, hyperlordosis of the upper cervical spine, and the forward-head posture. *Reproduced with permission from Joseph E. Muscolino. Artwork by Giovanni Rimasti.*

5

Rounded thoracic spine also leads to protracted scapulae and medially rotated humeri. *Reproduced with permission from Joseph E. Muscolino. Artwork by Giovanni Rimasti.*

EFFECT ON THE CERVICAL SPINE

Once we flex the thoracic spine forward, the cervical spine must begin its posture on the superior aspect of the body of T1 that is now more vertically oriented. This projects the lower neck anteriorly, continuing the path of the upper thoracic spine, causing the lower cervical spine to be hypolordotic. As a necessary compensation, the upper cervical spine must become hyperlordotic to bring the eyes and inner ears level for proprioception (Image 4). These dysfunctional cervical postures alter the balance of weight-bearing through the cervical spinal joints. Hypolordosis increases weight-bearing through the discs, increasing the likelihood of disc pathology. Hyperlordosis increases weight-bearing through the facets, increasing the likelihood of facet irritation and degenerative osteoarthritic changes. These conditions, in turn, increase the likelihood of nerve compression in the intervertebral foramina.

EFFECT ON FORWARD-HEAD CARRIAGE

This altered cervical posture also results in a forward-head carriage, in which the center of weight of the head is located anterior to the trunk, over thin air (Image 4). This imbalanced posture requires the posterior soft tissues to work harder to keep the head from falling into flexion due to gravity, resulting in tighter posterior extensor cervicocranial musculature, likely causing neck pain, myofascial trigger point referral pain, and tension headaches.

EFFECT ON SHOULDER POSTURE

Once the thoracic spine rounds forward, the shoulder girdles cannot maintain a posterior posture and they fall into protraction; the arms follow suit by falling into medial/internal rotation (Image 5). These upper extremity distortional postures often result in increased stress on the muscles, resulting in tightness, pain, trigger point formation (along with referral of pain), and fascial adhesions. Further, a medially rotated humerus decreases abduction and flexion range of motion of the arm.

To experience the effects of this rounding, first try abducting and/or flexing your arm with it being medially rotated. Then, repeat the motion with the arm laterally rotated, and note the difference in range of motion. A medially rotated arm also increases the likelihood of shoulder impingement syndrome of the supraspinatus tendon and subacromial bursa (due to the approximation of the greater tubercle against the acromion process of the scapula above).

EFFECT ON THORACIC OUTLET SYNDROME

If this were not enough, UCS also increases the likelihood of all three myofascial forms of thoracic outlet syndrome: pectoralis minor syndrome, costoclavicular syndrome, and anterior scalene syndrome. Pectoralis minor syndrome is due to the locked-short pectoralis minor; costoclavicular syndrome is due to the collapsed posture of the clavicle against the first rib; and the anterior scalene syndrome is due to the adaptive shortening of the scalene musculature.

EFFECT ON BREATHING

UCS even inhibits our ability to breathe. This is easy to demonstrate. Flex your thoracic spine, protract your shoulder girdles, medially rotate your arms, and try to take in a deep breath. It is difficult, correct? Now, open up your body by extending your thoracic spine, retracting your shoulder girdles, and laterally rotating your arms. Take in a deep breath, and notice how much more easily you can breathe deeply. A flexed, protracted, medially rotated posture inhibits the ability of the thoracic cavity to expand, limiting our ability to intake air, as well as oxygenate our blood and all the tissues of our body.

EFFECT ON THE LUMBAR SPINE

Effects of a rounded thoracic spine can even be felt inferiorly at the lumbar spine. By early middle age, a hyperkyphotic thoracic spine tends to become rigid, thereby limiting thoracic extension and other ranges of motion. This places a greater demand on the lumbar spine to extend (Image 6), resulting in increased compression force on the lumbar facet joints, likely causing facet irritation, osteoarthritic degenerative changes (and possible foraminal encroachment and nerve impingement), joint dysfunction, and low-back pain. Low-back pain often then results in protective spasming of the nearby paraspinal extensor musculature, causing further joint dysfunction and low-back

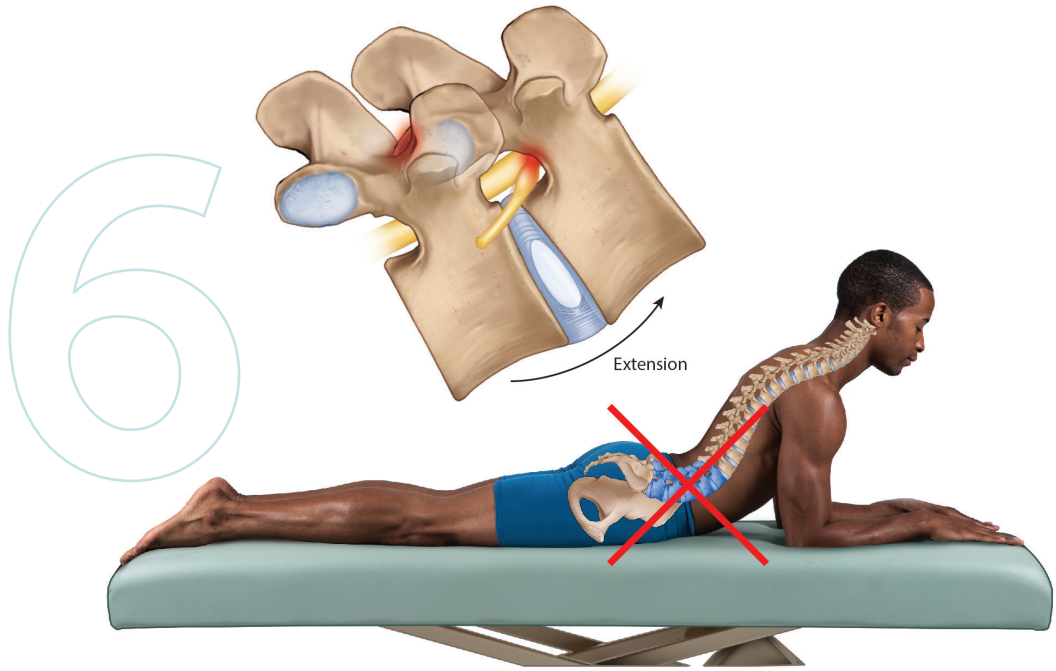

A rigid thoracic spine that is stuck in flexion places a greater demand on the lumber spine to extend. *Reproduced with permission from Joseph E. Muscolino. Artwork by Giovanni Rimasti.*

Lower-Crossed Syndrome and the Thoracic Spine

Rounded-back thoracic hyperkyphosis is often caused by and accompanied by a general rounding of the entire spine, including the lumbar region (see Image 2). In these cases, the lumbar spine reverses its lordosis to become kyphotic and the thoracic spine continues this kyphosis, resulting in rounded posture of the entire thoracolumbar spine. However, even a hyperlordotic lumbar spine can result in a rounded hyperkyphotic thoracic posture (see accompanying image). Lumbar hyperlordosis is a prominent feature of the postural distortional pattern known as *lower-crossed syndrome* (LCS; Image 3). The hallmark feature of LCS is an excessively anteriorly tilted pelvis, which then results in a hyperlordotic (in other words, hyperextended) lumbar spine. With LCS, because the lumbar spine is hyperextended, the center of weight of the trunk moves posteriorly. As a compensation to bring the trunk's center of gravity back anteriorly, the thoracic spine must increase its flexion (kyphosis), thereby resulting in an excessively rounded thoracic spine (with all of its sequelae described in this article).

Lower-crossed syndrome and the thoracic spine. *Reproduced with permission from Joseph E. Muscolino. Artwork by Giovanni Rimasti.*

Motion palpation assessment of the thoracic spine into extension. *Reproduced with permission from Joseph E. Muscolino.*

pain. It is important to note that rigidity of the thoracic spine also impacts the cervical spine by similarly requiring it to increase its range of motion to compensate for the rigid hypomobile thoracic spine. This places increased stress on the musculature and joints of the cervical spine, resulting in further pain and dysfunction there as well.

ASSESSMENT OF ROUNDED BACK

Assessment of a rounded-back posture is straightforward. Simply observe the client from the side and assess the degree of the thoracic kyphotic curve. This should be followed by palpation of the pectoral musculature, as well as palpation of the extensor musculature of the thoracic spine and retractor musculature of the shoulder girdle. Because chronic rounded-back posture results in rigidity of the spine being stuck in flexion, gentle but firm palpation of the thoracic spinal joints should be done by challenging these joints to move into extension. This is accomplished by pressing (gently but firmly) directly midline on the thoracic spine of the prone client with the palm of the hand; placing the spinous processes in the intereminential groove (the groove between the thenar and hypothenar eminences); and feeling for the end-feel motion of the joints (Image 7). A healthy joint has a firm but slightly elastic springy bounce at end-feel. If, instead, the end-feel is rigid (like hitting a concrete wall), then the joints being assessed are locked/hypomobile, likely due to intrinsic muscular spasming and fascial adhesions. Because thoracic rigidity can cause dysfunctional compensations elsewhere, if thoracic hypomobility is identified, it is important to then assess for all of the possible related conditions.

TREATMENT OF ROUNDED BACK

All effective clinical orthopedic manual therapy treatment should be directed at the fundamental underlying biomechanical and neurologic mechanisms causing the rounded-back condition. With thoracic rounded back, the underlying mechanism is a chronic hyperflexed posture of the thoracic spine that then creates locked-short pectoral musculature anteriorly, locked-long thoracic musculature posteriorly, and hypomobile thoracic joints.

Treating the Myofascial Tissue

Treatment of myofascial tissue should be directed toward loosening the anterior musculature, and loosening and strengthening the posterior musculature. Therefore, the target muscles to which treatment must be directed are the pectoral muscles anteriorly (pectoralis major, pectoralis minor, and the subclavius), and the posterior muscles of thoracic spinal extension (erector spinae and transversospinalis), shoulder girdle retraction (rhomboids and trapezius, especially middle trapezius), and humeral medial rotation (subscapularis, teres major, latissimus dorsi, anterior deltoid, and pectoralis major). There is no one magical soft-tissue technique for loosening musculature, but a general approach is to use moist heat, followed by deep-tissue massage and then stretching.

If it is within your scope of practice, it is important to recommend to the client to strengthen the musculature of thoracic extension, shoulder girdle retraction, and humeral lateral rotation.

Treating the Thoracic Joints

All of this wonderful myofascial work will be ineffective if the client's thoracic spinal joints are rigid and stuck in flexion. For these clients, it is imperative that Grade IV joint mobilization is performed, especially directed toward extension.* Grade IV joint mobilization involves repeated gentle but firm oscillations directed toward moving the joint into the ranges of motion that are decreased. These oscillations are usually repeated for approximately 15–30 seconds. For extension joint mobilization, the therapist simply directs the force from posterior to anterior midline on the spine of the prone client. In other words, it is performed in an identical manner to the motion palpation assessment technique (Image 7). If this treatment technique is not within your scope of practice, then the client should be referred to a soft-tissue-oriented chiropractor or osteopath for adjunctive care. Note: be aware that joint mobilization is contraindicated if the client has any hypermobility/instability of tissue locally where the treatment is being rendered (for example, osteoporosis/osteopenia).

Self-Care Recommendations

Following in-office treatment, home care consists of a hot shower (or other form of moist heat) followed by foam rolling or

** Grade IV joint mobilization is legal and ethical for most massage therapists in the United States and Canada. To be sure that this technique is within your scope of practice, please check with your state licensing body. It should be emphasized that Grade IV joint mobilization does not involve a fast thrust.*

working with therapeutic balls to address the myofascial tissue. Stretching after moist heat application is also extremely valuable. One easy and excellent way to stretch the thoracic spine into extension is to use a gym ball (Image 8). Strengthening exercises for spinal extension, shoulder girdle retraction, and glenohumeral lateral rotation should also be done on a regular basis.

Using a gym ball to stretch and open the thoracic spine into extension. *Reproduced with permission from Joseph E. Muscolino. Artwork by Giovanni Rimasti.*

Addressing Posture

Finally, given that the root cause of thoracic spinal hyperkyphosis is chronically assuming a rounded-forward posture into flexion, it is imperative that the client begins to make lifestyle changes that eliminate these postures. For this reason, it is important to counsel the client about a wide range of postures, especially when using a desktop, laptop, tablet, or smartphone; postures when writing or reading a book; postures when driving; and any other posture that might involve working down in front of the body.

Treating the Sequelae

Given that a rounded thoracic postural distortion pattern can spin off and create other secondary problems, it is important to not only assess for these secondary conditions, but to also treat them as needed. Often, when the initial primary cause of a secondary condition is removed, the secondary condition resolves on its own without needed treatment. However, when the secondary condition is allowed to be present for a long period of time (months, years, or even decades), it becomes entrenched in the body. In these cases, it is usually not enough to simply remove the initial cause; rather, the secondary conditions must be individually targeted and treated.

MOTIVATIONS FOR TREATMENT

The two most common signs and symptoms that direct a client toward seeking manual therapy treatment are pain and stiffness. Pain usually indicates that tissue damage is occurring and is probably the primary reason clients seek manual therapy. Stiffness (loss of range of motion), which usually indicates taut soft tissues, is far less powerful toward compelling a client to seek care. Decreased range of motion is often ignored or not even noticed, especially when it occurs in small increments over long periods of time. This, unfortunately, is the circumstance with rounded-back posture. Because the progressively greater thoracic kyphosis occurs so insidiously—often over months, years, or even decades—the client pays little or no attention to it. Even becoming self-aware of the distortional posture is not that noticeable to the client, because looking in the mirror affords the client an anterior view, which does not show the condition well; a lateral view is usually needed to appreciate the extent of the rounded posture that is occurring.

THE THORACIC SPINE AS SILENT SABOTEUR

The major reason rounded-back posture does not motivate the client to seek care is that the ensuing rigidity of the thoracic spine rarely causes pain. As a result, by the time the client notices a problem, it has usually been chronic for years and decades, and is now much more firmly entrenched. By this point in time, it has set in motion the other postural distortional sequelae of the cervical spine, head, shoulder girdles, arms, and lumbar spine. It is often the pain in these other regions that initially motivates the client to seek manual therapy. While direct manual therapy at this point is needed for these other regions of the body for immediate alleviation of their symptoms, manual therapy to the asymptomatic thoracic region is crucially important for long-term relief. For example, when clients come in with neck pain, I often like to tell them that if they want their neck to feel better today, I will work the neck today; but if they want their neck to feel better six months from now, I need to work their thoracic spine. It is simply not possible for a neck to be functional and healthy if the thoracic spine is hyperkyphotic! The same concept often holds true for the shoulders or low back. For all these regions, the thoracic spine is truly a *silent saboteur* that must be considered and addressed when performing clinical orthopedic manual therapy care with our clients. **m&b**

Joseph E. Muscolino, DC, has been a massage therapy educator for more than 25 years and is the author of numerous textbooks on manual therapy, including *The Muscle and Bone Palpation Manual* (Elsevier, 2016), *Kinesiology* (Elsevier, 2011), *The Muscular System Manual* (Elsevier, 2017), *Manual Therapy for the Low Back and Pelvis* (Lippincott Williams & Wilkins, 2015), and *Advanced Treatment Techniques for the Manual Therapist: Neck* (Lippincott Williams & Wilkins, 2013). He teaches continuing education workshops around the world, including a certification in Clinical Orthopedic Manual Therapy (COMT). Visit www.learnmuscles.com for more information.