# palpation of the anterior neck

The anterior neck is problematic for many massage therapists. You may avoid working this region for two reasons. First, many endangerment sites are located in the anterior neck, including the trachea, thyroid gland, brachial plexus of nerves, and carotid artery. Second, working in this region can be uncomfortable if you are not skilled and familiar with it. The contours of the transverse processes of the vertebrae are rather sharp and having soft tissue pressed against them can be painful. Even with these concerns, however, working the anterior neck can be very beneficial for the health of your client, especially one who has suffered a whiplash injury. Therefore, learning how to work the musculature of the anterior neck can be a valuable addition

RESOURCES
For more information go to **www.medlineplus.gov** and search under "anterior neck."

**FIGURE 1A** is a superficial anterior view. The platysma is shown on the right and removed on the left.

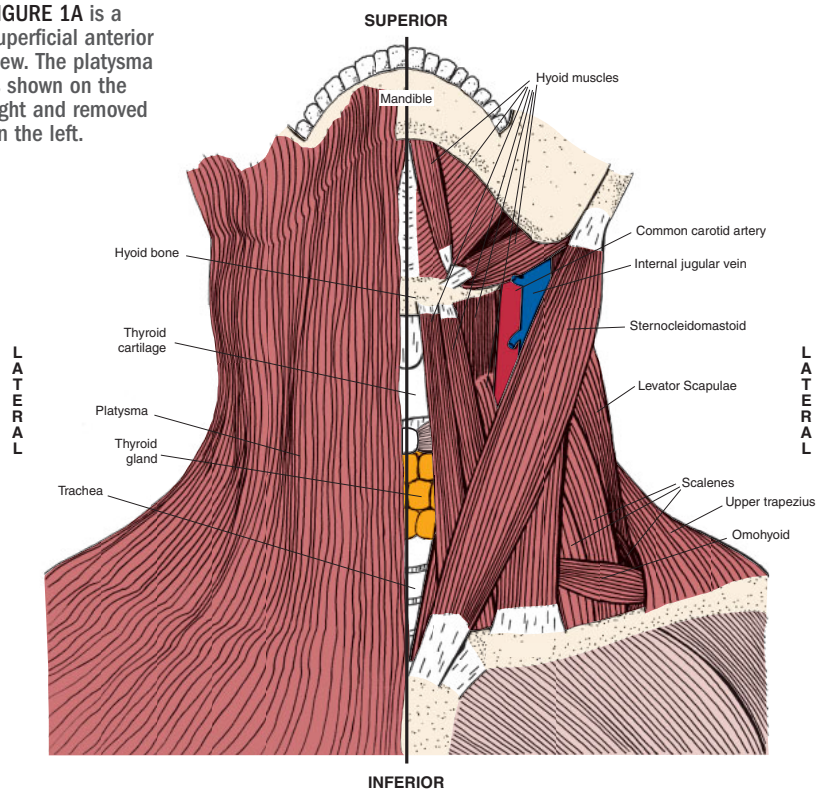


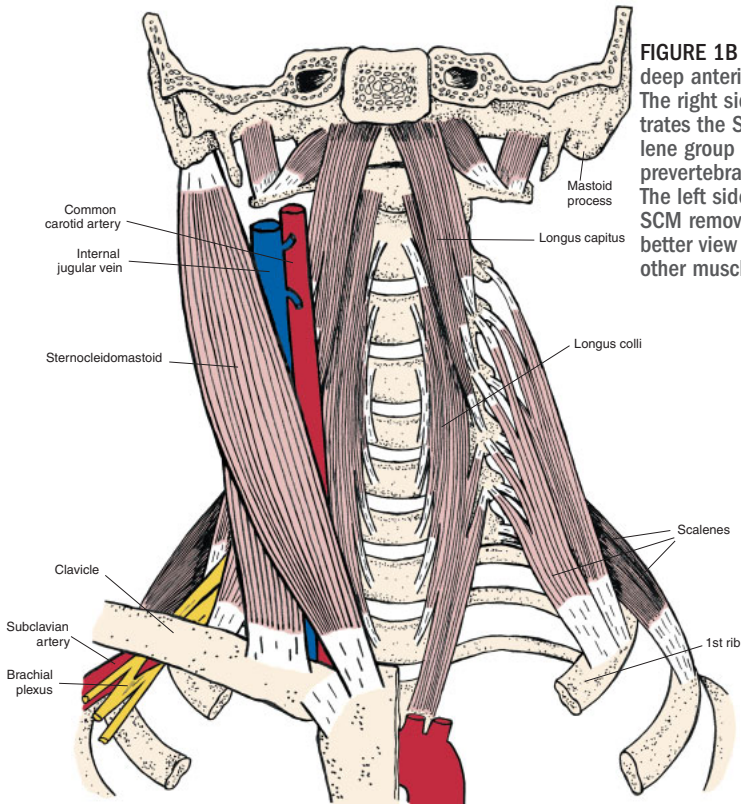


**FIGURE 1B** is a deep anterior view. The right side illustrates the SCM, scalene group and the prevertebral group. The left side has the SCM removed for a better view of the other muscles

to a massage therapist's practice. And the first step to learning how to safely and effectively work the anterior neck is learning how to identify, locate and palpate the muscles of this region.

The anterior neck is home to a number of important muscles, including the sternocleidomastoid (SCM), scalene group and the prevertebral group of muscles (Figures 1A and 1B).* Functionally, the muscles of the anterior neck are flexors of the neck at the spinal joints. Consequently, during a typical whiplash accident when a person's head and neck are forcibly thrown back into extension, the muscles of the anterior neck are excessively stretched, triggering the muscle spindle stretch reflex. This results in tightness and spasming of the muscles of the anterior neck. Beyond local pain from the tightness of these muscles, tightness of the SCM is associated with proprioceptive disturbances of the neck, often resulting in dizziness. Tightness of the scalenes can be associated with compression upon nerves that provide innervation to the upper extremity. Finally, tightness of the prevertebral muscles can cause referral pain that is interpreted as a sore throat. Given the prevalence of whiplash injuries, and the variety and extent of signs and symptoms that can result, there can be tremendous value in working the anterior neck musculature of our clients!

### The Scalene and Prevertebral Muscles

While most of you are knowledgeable and comfortable working the SCM, the scalenes and prevertebral muscles are less often addressed. We will begin by locating and palpating the SCM. The SCM will then be used as a landmark for the location and palpation of the scalene and prevertebral muscle groups.

The SCM has two heads—a sternal

* The hyoid group of muscles is also located in the anterior neck. This article will not address their palpation.

*Figure 1A courtesy The Muscular System Manual by Joseph Muscolino. Mosby, 2005. Figure 1B courtesy of Joseph Muscolino.*

and a clavicular head. Inferiorly, the sternal head attaches onto the manubrium of the sternum, and the clavicular head attaches onto the medial clavicle. Both heads conjoin and attach superiorly onto the mastoid process of the temporal bone and superior nuchal line of the occipital bone. The SCM can be easily palpated with the client seated or supine. With the client seated, stand to the side that will be palpated. Ask the client to first rotate the head and neck at the spinal joints to the opposite side (contralateral rotation) and slightly laterally flex the head and neck to the same side (ipsilateral lateral flexion) (Figure 2A). Now resist the client from further lateral flexion (Figure 2B) and the two heads of the SCM will be visible and palpable. It is important to make sure that the client maintains the contralateral rotation; this is especially so for the sternal head because this head is more active in creating the rotation component of the SCM's actions. If the clavicular head is not readily palpable, ask the client to increase the force of resistance of ipsilateral lateral flexion because the clavicular head is more active in creating the lateral flexion component of the SCM's actions.

After palpating the entire length of both heads of the SCM* with the muscle contracted, palpate the SCM again while it is relaxed so that its resting baseline tone can be assessed. When palpating the SCM, be careful not to place excessive pressure upon the carotid artery because this will stimulate a neurologic reflex that can lower blood pressure; you can tell if you are pressing upon the

**FIGURE 2A** shows the beginning position for seated palpation. Stand behind the client and to the side that will be palpated; the client rotates the head and neck toward the opposite side and slightly laterally flexes the head and neck toward the same side.

**FIGURE 2B** illustrates the therapist offering resistance to further lateral flexion of the head and neck toward the same side; this requires the SCM to contract, making it more palpable.

**FIGURE 2C** demonstrates supine palpation. The client first rotates the head and neck to the opposite side and then lifts the head and neck off the table, creating a contraction of the SCM.