



## freedom from thoracic outlet syndrome

The name thoracic outlet syndrome (TOS) refers to three different conditions: anterior scalene syndrome, costoclavicular syndrome and pectoralis minor syndrome. The reason that these three conditions are all grouped together as TOS is that they are all entrapment syndromes of the brachial plexus of nerves and/or the subclavian artery/vein in the region where the thorax “outlets” into the upper extremity (Figure 1). As a result, all three types of TOS can result in nerve or vascular impingement, resulting in symptoms in the upper extremity.

### Types of TOS

With all three types of TOS, the name describes the location of the impingement. In anterior scalene syndrome, the brachial plexus and subclavian artery run between the anterior and middle scalene muscles in the anterolateral neck. If the scalene muscles are tight, per-

haps due to a whiplash accident, impingement may occur. In costoclavicular syndrome (“cost” means rib), the brachial plexus and subclavian artery and vein run between the first rib and clavicle in the medial pectoral region. If the posture of the relationship of the clavicle and first rib changes and they approximate each other—as often happens with rounded and slumped shoulders—impingement may occur. In pectoralis minor syndrome, the brachial plexus and subclavian artery and vein run between the pectoralis minor muscle and the rib cage in the lateral pectoral region. Impingement can also occur if the pectoralis minor is tight; this often happens with slumped shoulder postures as well.

### The Brachial Plexus

The brachial plexus of nerves is created by a mixing of the C5, C6, C7, C8 and T1 spinal nerve roots. As a

### RESOURCES

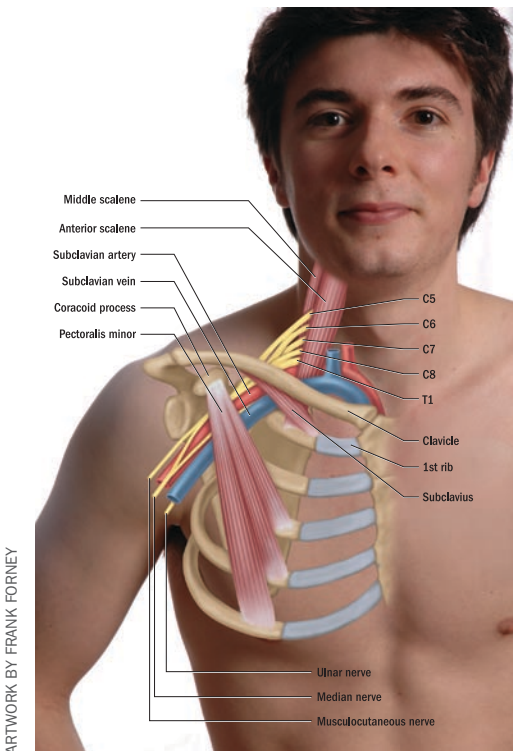
For more information about TOS go to [www.nlm.nih.gov/medlineplus/thoracicoutletsyndrome.html](http://www.nlm.nih.gov/medlineplus/thoracicoutletsyndrome.html).

result of this intermixing, the brachial plexus creates five major nerves: the median, radial, ulnar, musculocutaneous and axillary (Figure 2). These nerves carry both sensory innervation and motor innervation that supply the upper extremity. Sensory information travels upward from the upper extremity through sensory neurons of the brachial plexus nerves and enters the central nervous system (CNS) to alert us to the sensations that we feel in the upper extremity. Motor information travels downward from the CNS through motor neurons of the brachial plexus nerves and enters the upper extremity to direct its musculature to contract as needed. Therefore, TOS can cause sensory and/or motor symptoms in the upper extremity depending upon which aspect of a brachial plexus nerve is impinged. Typical sensory impingement symptoms include pain (sharp or dull), numbness and tingling; the typical motor impingement symptom is weakness of the affected musculature. Further, because the brachial plexus innervates the entire upper extremity (arm, forearm and hand), these symptoms can occur anywhere within the upper extremity.

usually manifests in color changes such as blanching (a pale or whitish appearance) or cyanosis (bluish/purplish appearance) of the skin. Both of these result from a loss of blood supply to the tissues. Even though TOS brachial plexus nerve impingement is more common and usually more serious than TOS vascular impingement, subclavian artery impingement is particularly important because therapists use impingement of the subclavian artery to assess TOS.

**Importance of TOS Assessment**  
Because symptoms of TOS can be located anywhere within the upper extremity, TOS may be misdiagnosed in clients by physicians and other qualified health care professionals. Mistakenly, clients are often told that they have a pathologic condition of a cervical disc or carpal tunnel syndrome because these conditions also cause nerve impingement with sensory/motor symptoms in the upper extremity. Given the possibly serious recourse to surgery for these other conditions, accurate assessment of TOS in our clients is of paramount importance. Another important reason to accurately assess TOS in our clients is that all three types of TOS respond so well to massage and bodywork.

**Method of TOS Assessment**  
With all three types of TOS, you can begin by assessing the strength of your client's radial pulse when he is relaxed and in a neutral position (Figure 3). The client is then passively moved or asked to move actively into a particular position; the strength of the client's radial pulse is assessed again. These assessment procedures for TOS follow logically from the mechanism



**Figure 1** is an anterior view illustrating the relationship of the brachial plexus of nerves and the subclavian artery and vein to adjacent structures. These nerves and vessels may be impinged in three locations where the thorax outlets into the upper extremity: 1) between the anterior and middle scalenes, 2) between the clavicle and first rib and 3) between the pectoralis minor and the rib cage.

**Subclavian Artery and Vein**

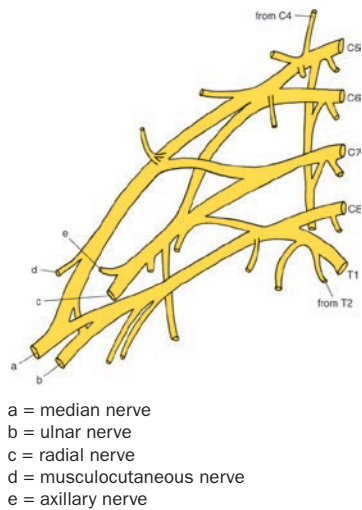
The subclavian artery feeds oxygenated blood to all tissues of the upper extremity; the subclavian vein drains deoxygenated blood from all tissues of the upper extremity. While the subclavian artery can be entrapped in all three TOS impingement sites, the subclavian vein does not run between the anterior and middle scalenes, so it cannot be involved in anterior scalene syndrome. Compression of the subclavian vessels results in altered blood flow in the upper extremity. This

of the type of impingement in each of the three types.

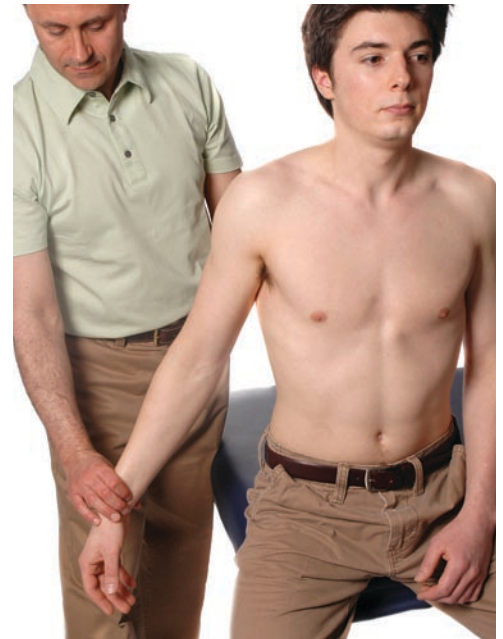For example, anterior scalene syndrome causes an impingement due to tight anterior and middle scalene muscles. Therefore, the assessment procedure is to pull these muscles taut by stretching them. This is accomplished by asking the client to do the opposite actions of what the scalenes would do. Because these muscles do flexion, contralateral (opposite sided) rotation, and ipsilateral (same sided) lateral flexion of the neck at the spinal joints, if we ask the client to do extension, ipsilateral rotation, and contralateral lateral flexion, the scalenes will be stretched taut (Figure 4). If they were tight to begin with, when they are stretched and pulled taut by this procedure, they would further compress the brachial plexus and subclavian artery.

Objectively, this impingement is assessed by palpating for a decrease in strength of the radial pulse at the wrist. This would indicate impingement of the subclavian artery and is a positive test result for anterior scalene syndrome. This procedure is called Adson's test. The importance of this assessment procedure is that if the subclavian artery is being impinged, we can assume that the brachial plexus of nerves also is being impinged.

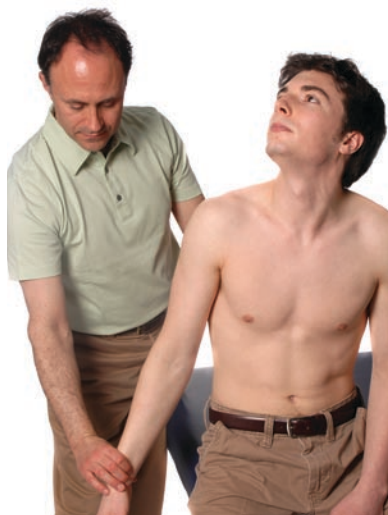Similarly, costoclavicular syndrome is caused by impingement occurring between the clavicle and first rib. To assess this, the client must assume a position that further approximates these two structures. This is accomplished by asking your client to stick his chest out (pushing the rib cage and specifically the first rib anteriorly against the clavicle) and pull the shoulder girdle back and down (pulling the clavicle pos-



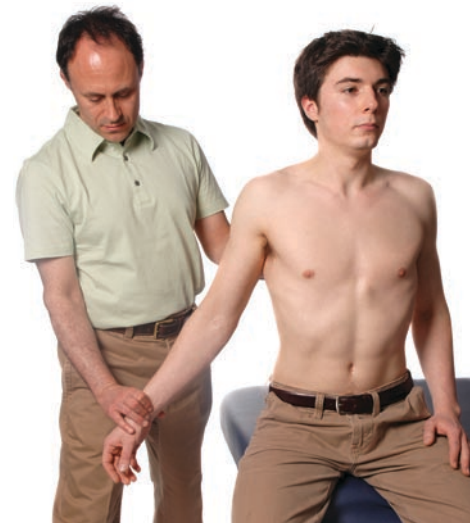**Figure 2** illustrates the brachial plexus. Five major nerves are formed by the brachial plexus: the median, radial, ulnar, musculocutaneous and axillary.



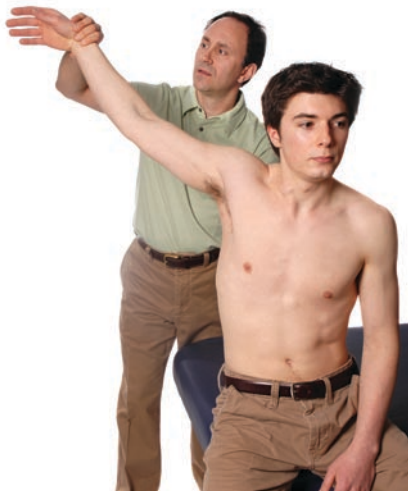**Figure 3** illustrates assessment of the strength of the client's radial pulse when the client is relaxed and in a neutral position. This is done at the beginning of the assessment procedure for each of the three TOS conditions.



**Figure 4** illustrates Adson's test for anterior scalene syndrome, one of the three types of TOS. The client is asked to ipsilaterally rotate, contralaterally laterally flex, and extend his neck at the spinal joints, while the radial pulse is palpated. Decrease in strength of the radial pulse is positive for anterior scalene syndrome.



**Figure 5** illustrates Eden's test for costoclavicular syndrome, a second type of TOS. The client is asked to pull the shoulder girdle back and down and push the chest forward, while the radial pulse is palpated. Decrease in strength of the radial pulse is positive for costoclavicular syndrome.



**Figure 6** illustrates Wright's test for pectoralis minor syndrome, the third type of TOS. The client's upper extremity is passively moved up and back, while the radial pulse is palpated. Decrease in strength of the radial pulse is positive for pectoralis minor syndrome.

teriorly and inferiorly against the first rib), similar to the military posture of attention (Figure 5). Again, weakening of the strength of the radial pulse would be considered to be a positive sign. This procedure is called Eden's test.

Pectoralis minor syndrome is caused by a tight pectoralis minor muscle compressing the brachial plexus and/or subclavian vessels against the rib cage. The assessment procedure for this type of TOS would be to ask your client to bring his arm up and back. This position stretches and pulls the pectoralis minor taut against the rib cage (Figure 6). Weakening of the strength of the radial pulse would be positive for the presence of pectoralis minor syndrome. This procedure is called Wright's test.

All three test procedures may be augmented by asking your clients to take in and hold a deep breath. With Adson's test, breathing in causes a further contraction and "hardening" of the scalenes (because these muscles can lift the ribs for inspiration) while they are being pulled taut. With Eden's test, it causes the rib cage to lift, bringing the first rib closer to the clavicle and decreasing the space between these two structures. With Wright's test, breathing in causes a further contraction and "hardening" of the pectoralis minor while it is being pulled taut against the rib cage. Most important when learning these TOS assessment procedures is to understand why the procedure is being done. If the underlying mechanism is understood, the procedure can be reasoned out instead of memorized.

#### Therapy for TOS

The therapy approaches for the types

of TOS also follow directly from an understanding of the mechanism of the condition. For example, the approach for anterior scalene syndrome is to loosen the tight scalenes by massage and stretching. For pectoralis minor syndrome, therapy is geared at both loosening the tight pectoralis minor via massage and stretching, and also recommending exercises that strengthen the antagonistic musculature of retraction of the scapula (e.g., rhomboids and middle trapezius). For costoclavicular syndrome, therapy is geared at loosening the tight muscles that cause the poor posture of rounded and slumped shoulders (pectoralis major and minor as well as subclavius). It is also important to recommend that muscles that resist this postural pattern are strengthened (rhomboids and middle trapezius).

#### Summary

All three types of TOS are easy to assess and their treatment is ideally suited to massage, bodywork and exercise. Therefore, awareness and knowledge of TOS and the procedures to assess it can make a critical difference in the care of our clients.



*Joseph E. Muscolino, DC, is an instructor at the Connecticut Center for Massage Therapy. He is also the*

*author of The Muscular System Manual, Kinesiology: The Skeletal System and Muscle Function, and The Musculoskeletal Anatomy Coloring Book (Elsevier, 2006). Visit Joseph's website: [www.learnmuscles.com](http://www.learnmuscles.com).*