



carpal tunnel syndrome

The word carpal means wrist. Therefore, the carpal tunnel is a tunnel that is formed by the structural configuration of the wrist (carpal) bones. Carpal tunnel syndrome (CTS) is a pathologic condition in which the median nerve is compressed within the carpal tunnel. CTS can affect anyone, but is of special importance to manual therapists because of the heavy physical stresses that we place on our hands and wrists.

STRUCTURE. The carpal tunnel can be seen best by looking at a proximal-to-distal (down the forearm into the hand) view (Figure 1). The carpal bones project anteriorly on both the ulnar and radial sides: the pisiform and hamate on the ulnar side, and the trapezium and scaphoid on the radial side. This creates a central depression, or tunnel in which the carpal bones form the floor and walls of the tunnel. The ceiling is formed by a dense fibrous fascial structure known as the transverse carpal ligament (also known as the flexor retinaculum). The carpal tunnel is important because it creates an enclosed and protected space that affords safe passage for the median nerve from the forearm into the

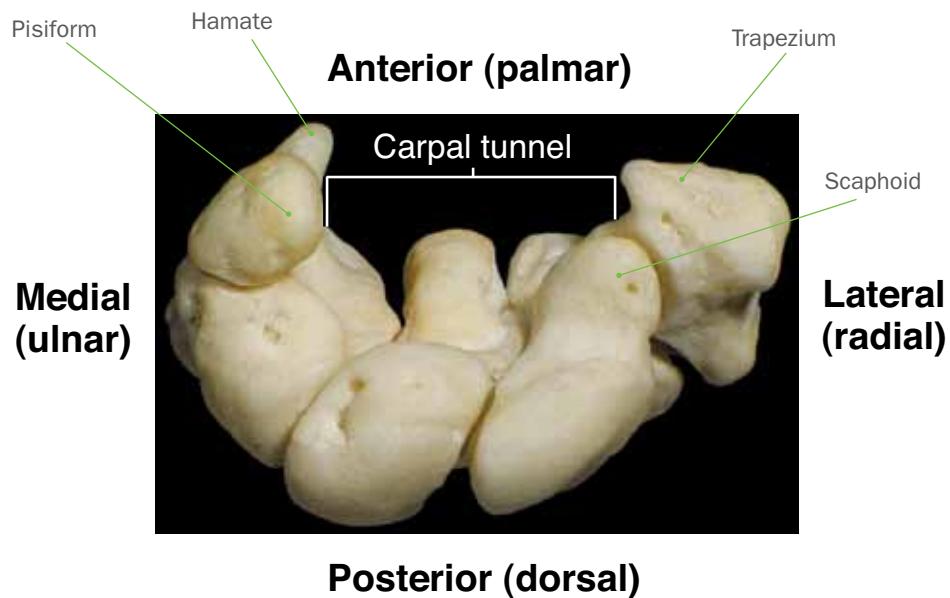
hand. Also contained within the carpal tunnel are nine long finger flexor tendons: four tendons of the flexor digitorum superficialis, four tendons of flexor digitorum profundus, and the tendon of the flexor pollicis longus (Figure 2).

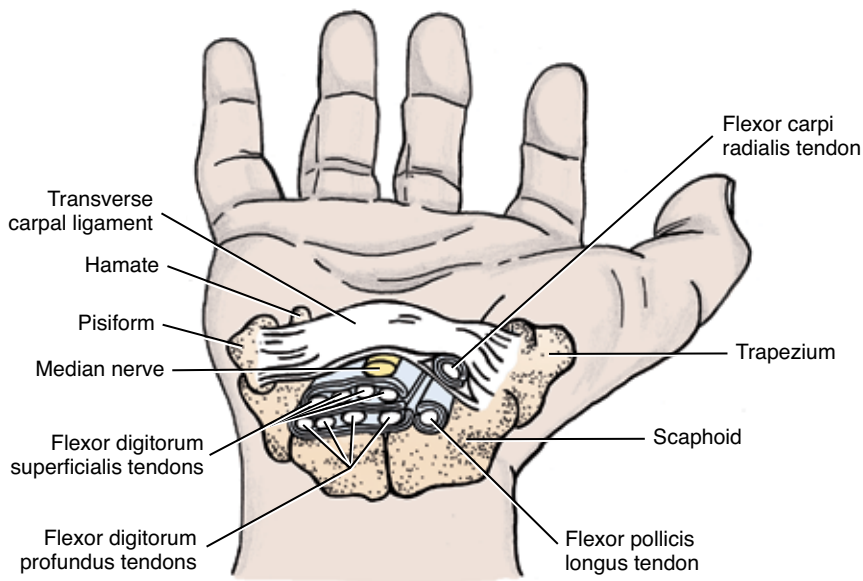
NERVE COMPRESSION. Ironically, the feature that makes the carpal tunnel valuable—creating an enclosed and protected space that protects the median nerve—is the same feature that can lead to CTS. When structures within an enclosed space are injured, the swelling that occurs has nowhere to escape. In the case of CTS, this swelling results in compression of the median nerve. If this condition becomes chronic, fibrous scar tissue adhesions may form, which can further compress the median nerve.

CAUSES. Injury to the carpal tunnel can occur through macrotrauma or repeated microtrauma. A typical macrotrauma is a fall on an outstretched hand. Repetitive microtrauma, which is more often the causative agent, may occur due to a number of poor postures and/or movement patterns.

For example, maximally flexing and/or extending the hand at the wrist joint can be problematic because these postures increase pressure within the carpal tunnel. Maximal extension is more often the culprit, especially

FIGURE 1
The carpal tunnel is formed by the carpal bones of the wrist.





CTS can affect anyone, but is of special importance to manual therapists because of the heavy physical stresses that we place on our hands and wrists.

FIGURE 2 Structures located within the carpal tunnel. (Note: The flexor carpi radialis tendon travels in a separate fascial compartment; it is not located in the carpal tunnel.)

if the hand is then pressed against a hard surface: examples include doing push-ups with hands flat on the floor, or opening a store door with the palms of the hands.

Another common postural microtrauma is extending the hand at the wrist joint while flexing the fingers at the metacarpophalangeal and interphalangeal joints. Extending the wrist joint not only increases pressure within the carpal tunnel, but also stretches and creates tension within the tendons of the long finger flexors; flexing the fingers then contracts their muscle bellies, further increasing the tension within these tendons. This faulty posture often occurs when typing at a key-

board without using a wrist support; or perhaps playing piano and letting the wrists drop below the level of the keys.

Another common repeated microtrauma is placing pressure through the palms of the hands. This is especially prevalent for manual therapists, especially those who continually use their palms to generate deep pressure into their clients. One other fairly common cause of CTS is general systemic swelling. The most common example of this phenomenon is the swelling that often occurs with pregnancy.

SIGNS AND SYMPTOMS. If we understand that the mechanism of CTS is median nerve compression, we don't need to memorize the signs and symptoms of this condition because we can reason them out. Compression upon a nerve can decrease its transmission by partially or entirely blocking the nerve cell's (neuron's) ability to carry its signal. Decreased signal conduction within the sensory neurons of a nerve can create numbness or decreased sensation (hypesthesia). Decreased signal conduction within the motor neurons of the nerve can result in weakness of the associated musculature.

Conversely, compression can increase nerve signal conductance if the compression irritates the neuron, causing it to send aberrant signals. If

CTS assessment tests do not have to be memorized. Similar to figuring out the signs and symptoms, knowing how to assess CTS is an extension of our understanding of the underlying pathomechanics of the condition.

sensory neurons are irritated, the client might have tingling, increased sensitivity or pain (hyperesthesia). If motor neurons are irritated, twitching in the musculature might occur. To determine where the symptoms of CTS would occur, we need to know the innervation distribution pattern of the median nerve, and where it's compressed.

LOCATION OF SENSORY SYMPTOMS. With CTS, median nerve compression occurs within the carpal tunnel, which is located immediately distal to the skin crease at the wrist, and is approximately 2 centimeters wide from proximal to distal. Any sensory signals that entered the median nerve proximal to the wrist do not pass through the carpal tunnel, and therefore would travel unimpeded back to the central nervous system. However, any sensations that entered the median nerve distal to the wrist would pass through the carpal tunnel and possibly be compressed and affected. For this reason, sensory symptoms of CTS compression upon the median nerve must, by definition, be restricted to the hand (Figure 3).

To determine exactly where within the hand these symptoms would be located, it is necessary to know the sensory dermatome distribution of the median nerve. The median nerve, through two branches, provides sensory innervation to the majority of the anterior side of the hand. The palmar branch of the median nerve innervates the palm; however, this branch enters the hand proximal to the carpal tunnel, so is not affected with CTS. The palmar digital branch of the median nerve innervates the anterior thumb, index, middle and (radial half of the) ring fingers. It also innervates the distal

ends of the same fingers on the posterior side (Figure 4). This branch enters the hand distal to the carpal tunnel. Therefore, sensory symptoms of CTS, when present, will occur within this region.

LOCATION OF MOTOR SIGNS AND SYMPTOMS. Similarly, motor symptoms of CTS must also be distal to the wrist. Any branches of the median nerve that carry signals to the anterior forearm would have already exited the median nerve and supplied its musculature before reaching the carpal tunnel. Therefore, CTS cannot directly cause weakness of forearm musculature. However, branches that exit the median nerve distal to the wrist could be blocked with CTS before reaching their destination. This can result in weakness of intrinsic hand musculature. Therefore, similar to sensory symptoms, motor signs and symptoms of CTS must be located within the hand (see Figure 3).

To determine exactly where in the hand motor signs and symptoms would manifest, it's necessary to know what hand muscles are innervated by the median nerve. They are the muscles of the thenar eminence (abductor pollicis brevis, flexor pollicis brevis, opponens pollicis) and the first two lumbricals manus. Because most of these muscles are involved with use of the thumb, CTS often results in grip weakness when holding an object between the thumb and other fingers. It is common for clients to unintentionally drop objects being held because of this weakness.

It should be noted that CTS cannot cause symptoms into the little finger, ulnar side of the ring finger or the dorsal surface of the hand because these regions are innervated by the ulnar and radial nerves, which do not travel within the carpal tunnel (see Figure 4). Also, CTS itself cannot directly cause forearm symptoms. However, because CTS involves tendons whose musculature is located in the forearm, these two regions are often causally linked. For example, overuse of the finger flexors of the forearm could cause both local forearm pain as well as CTS. But it is important to understand that the forearm pain is not directly caused by median nerve compression within the carpal tunnel.

ASSESSMENT. CTS assessment tests do not have to be memorized. Similar to figuring out the signs and symptoms, knowing how to assess CTS is an extension of our understanding of the underlying pathomechanics of the condition. If the median nerve is compressed due to

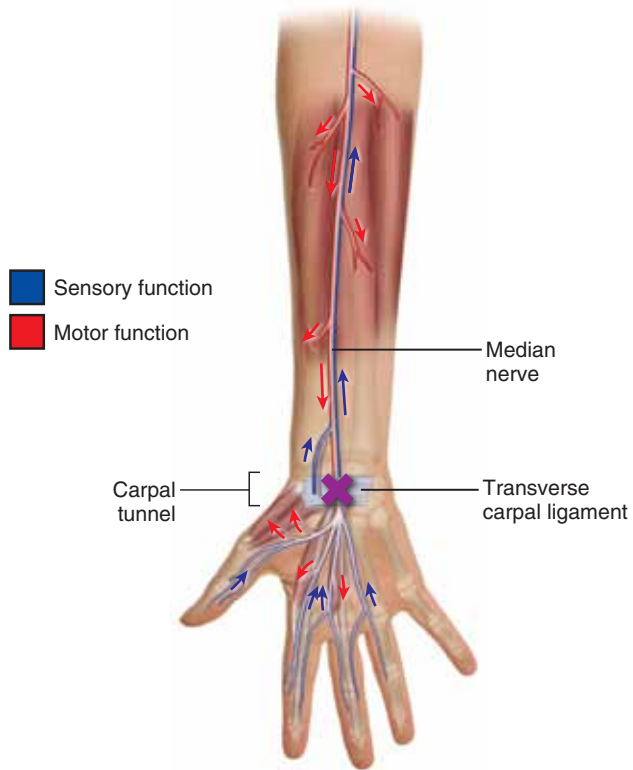


FIGURE 3
Blockage of sensory and motor neuron transmission in CTS

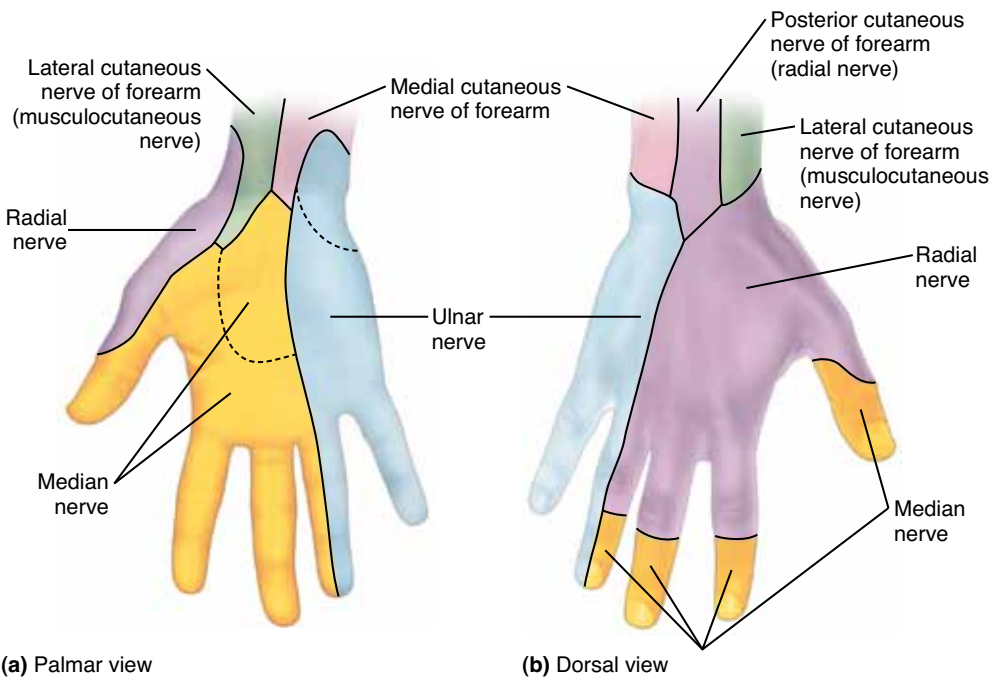


FIGURE 4
Sensory dermatomal distribution in the hand.
 A, Palmar (anterior) view.
 B, Dorsal (posterior) view.

CTS, then placing our client's hands in a position that further increases compression within the carpal tunnel should reproduce or increase characteristic symptoms of the condition.

You can accomplish this by asking the client to place their hands in full flexion as seen in Figure 5a. This is known as *Phalen's test*. Similarly, the client can be asked to place their hands in full extension as seen in Figure 5b. This is known as *Prayer sign*. For both of these assessment tests, the client is asked to hold the position for approximately 30–60 seconds. A third assessment test, known as *Tinel's sign*, is performed by tapping directly on the median nerve over the carpal tunnel (Figure 5c). In each case, the assessment test is positive if the client experiences symptoms within the median nerve distribution of the hand (as shown in Figure 4). Pain located only in the wrist as a result of these tests is not considered to be a positive sign of CTS because any sprain or tendinitis might elicit pain in these circumstances.

DIFFERENTIAL ASSESSMENT. CTS causes symptoms into the median nerve distribution of the hand. Therefore,

FIGURE 5A *Phalen's test*



FIGURE 5B *Prayer sign*.

FIGURE 5C *Tinel's sign*.



AMTA
RESOURCE

For information on thoracic outlet syndrome, see “Freedom from Thoracic Outlet Syndrome” in the Winter 2006 issue of *mt*

any condition that causes median nerve compression can mimic CTS and complicate assessment. Many conditions can do this, including pronator teres syndrome, all forms of thoracic outlet syndrome, and space occupying lesions in the neck (pathologic disc and bone spurs) that compress the spinal nerves that contribute to the median nerve. Certain myofascial trigger points can also refer pain into the median nerve distribution and mimic CTS. Even if positive findings are found for any one of these conditions, it's critically important that you continue to assess for all of the rest. It's not uncommon for a client to have contributions from more than one underlying pathologic condition.

TREATMENT. Treatment for CTS can be divided into two parts: self-care by the client and direct hands-on care by the therapist. Self-care is an extremely important aspect of the treatment plan. The client should be advised to avoid offending postures and activities as much as possible. It's also important to recommend a brace/splint for the wrist/hand that prevents extremes of flexion and extension. Wearing the brace at night is especially important, because many clients place their hands in unhealthy postures when sleeping. Frequent ice application should be recommended. Some studies have also found that taking vitamin B6 can be beneficial, and clients may also choose to take over-the-counter anti-inflammatory medication. If and when signs and symptoms of the condition have resolved, strengthening the forearm/hand musculature should be recommended.

Hands-on treatment can be challenging. Massage and other manual therapies are primarily geared toward relieving tension in taut soft tissues, but this is not the principal underlying mechanism of CTS. However, given that irritation of and tension in the tendons that travel through the carpal tunnel can contribute to pressure on the median nerve, working into the bellies of the flexors digitorum superficialis and profundus as well as the flexor pollicis longus can be very beneficial. Caution should be exercised if stretching these muscles is included in the treatment regimen, however, because the position of wrist extension needed to stretch these muscles can increase compression in the carpal tunnel. Gentle distal-to-proximal effleurage to dispel swelling, and mobilization of the carpal bones may also be of benefit.

REFERRAL. Whenever conservative manual therapy care is not successful, referral to a physician should be considered. This is especially true with any musculoskeletal condition that involves neural compression, like CTS does, because long standing pressure on a nerve can result in death of neurons, with consequent permanent sensory and/or motor loss. Damaged neurons can regenerate, but neurons that die cannot be replaced because peripheral neurons do not reproduce.

A physician can order electrophysiologic testing wherein conduction of the median nerve through the carpal tunnel is assessed. This testing is the most accurate way to diagnose CTS. Allopathic treatment includes prescription for steroidal anti-inflammatory (cortisone) medication, and cortisone injection into the carpal tunnel. If these treatment options fail, surgery is the final recourse. Surgery involves cutting (termed "releasing") the trans-

verse carpal ligament to open and release pressure within the carpal tunnel. When necessary, surgery is usually very successful. However, it should be kept in mind that in the long term, given the transverse carpal ligament's role of attaching across the carpal bones, cutting the transverse carpal ligament may lessen structural stability of the carpal tunnel, thereby predisposing the client to a reoccurrence. Strengthening the forearm/hand musculature is therefore advised.

CTS is an extremely common condition that the manual therapist will likely see in practice. It is also a condition that many therapists will experience at some point in their career. Therefore, a thorough understanding of this condition is important. Knowing the anatomy of the region and the underlying pathomechanics of CTS allows the therapist to be able to reason through and figure out the signs and symptoms of the condition, as well as how to assess it and choose the treatment options that will most likely benefit their clients. ■



Joseph E. Muscolino, DC, has been a massage

therapy educator for 24 years and currently teaches anatomy and physiology at Purchase College. He is the owner of The Art and Science of Kinesiology in Stamford, Connecticut, and the author of The Muscle and Bone Palpation Manual, The Muscular System Manual and Kinesiology, The Skeletal System and Muscle Function textbooks (Elsevier, 2009, 2010 and 2011). Visit Joseph's website at www.learnmuscles.com.