

## Palpation Assessment

by Joe Muscolino

### “NEVER TREAT WITHOUT AN ASSESSMENT”

There is an old adage in the world of medicine - never treat without a diagnosis. A similar principle can be articulated in the world of massage therapy - never treat without an assessment. After all, if a physical assessment has not been made, how do you know what the appropriate or best treatment is for the client; what areas should be worked and for how long; what strokes should be used; how deep should the pressure be; should stretching be done or perhaps joint mobilisation?

If no assessment is made, the likely scenario is that the therapist will perform a cookbook massage, a canned routine that every client receives. Although a cookbook massage can be generally therapeutic, altering local blood circulation, affecting sympathetic/parasympathetic nervous system balance, and providing the warmth of touch, it will probably not be effective in treating a specific musculoskeletal condition. To accomplish this, clinical orthopaedic massage is needed, that is, massage that specifically addresses the musculoskeletal conditions of the client on the table at that moment. And this requires a competent physical assessment.

### ASSESSMENT SKILLS

Competent orthopaedic assessment involves both the verbal history that covers the client's past and present status, and the physical assessment of the state of the client's tissues. Although massage therapists learn special assessment tests, such as Phalen's test for carpal tunnel syndrome or Wright's test for thoracic outlet pectoralis minor syndrome, by far the most important assessment skill that a massage therapist possesses is muscle palpation.

### MUSCLE PALPATION: ASSESSING MUSCLE TISSUE

Muscle palpation assessment involves using touch to assess the health of a target muscle and its fascial tissues. Is the muscle tight or loose? Is it inflamed or painful to touch? Does it contain adhesions, trigger points, or taut and tender bands? Assessing the muscle to answer these questions can point you towards the most effective treatment for the client.

However, all of this is of limited value if we do not know the target musculature we are assessing. Although it is possible to perform massage stroke manipulation to musculature without knowing what muscles we are working, possessing this knowledge can make our work much more effective – identifying the muscle alerts us to the direction of the fibres which helps determine the preferred direction of our strokes. It also helps us to understand and be aware of precautions and contraindications in the area. Further, it is difficult to know how to effectively stretch a tight muscle if we do not know what it is. But, perhaps most importantly, if we do not know which musculature is unhealthy, it is not possible to determine why the client is experiencing the condition. Given that unhealthy musculature often results from overuse, without identifying the muscle we cannot reason backwards to determine what the client is doing in their daily life to create the problem. This also means we cannot give accurate and helpful postural and movement self-care advice for the client when they are at home, at work and engaged in sports or other hobbies.

### MUSCLE PALPATION: LOCATING AND DISCERNING THE TARGET MUSCULATURE

The foundation of muscle palpation literacy lies in being able to accurately locate and discern the target musculature that is being worked. There is a science and an art to this aspect of muscle palpation. Following are the four major guidelines to follow when performing muscle palpation. Critically thinking through the application of these guidelines can greatly improve palpation skills.

#### Guideline 1 - Know the attachments of the target muscle

Knowing the attachments of the target muscle tells us where to place our palpating fingers. For example, if we know that the deltoid attaches from the clavicle and scapula to the deltoid tuberosity of the humerus, we also know that we need to place our palpating fingers on the proximal arm between those two attachment sites. If our target muscle is superficial and well developed, this may be all that we need to do to initially locate it. However, we still might not be sure of its exact borders. We might be able to locate the centre of the muscle belly but how will we know if we have strayed off the target muscle and onto adjacent musculature? And if the target muscle is deep and difficult to feel, simply placing our fingers between its attachments is clearly not enough. Therefore, we also need Guideline 2.

#### Guideline 2 - Know the actions of the target muscle

Knowing the actions of the target muscle provides us with the necessary information to ask the client to perform a joint action that will engage and contract that muscle. For example, we know that the deltoid abducts the arm at the glenohumeral joint so we can ask the client to perform this action and feel for the deltoid to palpably harden (Figure 1).



▲ **Figure 1:** Asking the client to abduct the arm at the glenohumeral joint engages and contracts the deltoid. From Muscolino JE: *The Muscle and Bone Palpation Manual, With Trigger Points, Referral Patterns, and Stretching*. St. Louis, 2009, Elsevier. Photo taken by Yanik Chauvin.

Continuing with this logic, we also know that the anterior fibres of the deltoid flex the arm at the glenohumeral joint so we can ask the client to flex the arm instead to locate the anterior deltoid.

Similarly, we can use extension of the arm for the posterior deltoid. If the deltoid hardens and the adjacent muscles and other soft tissues remain soft, then it is easier to discern its borders from adjacent soft tissues.

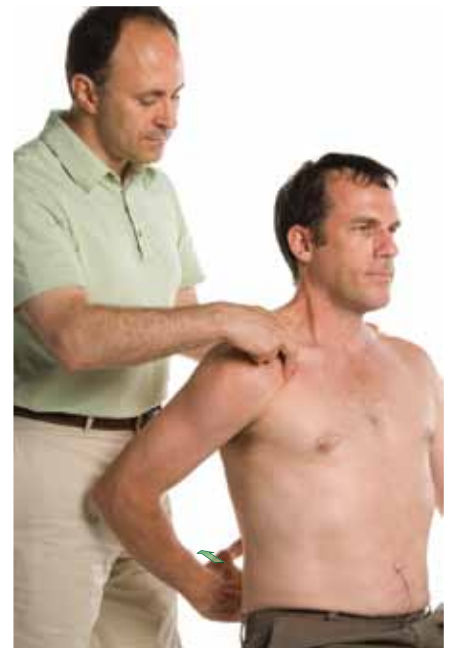### **Guideline 3 - Choose the best action of the target muscle**

Assuming that the target muscle has more than one action, it is not good enough to simply choose any of its actions to engage it. We need to choose the best action. This is where many errors in palpation protocols are made. The importance of this can be understood if we keep in mind that our goal is not just to have the target muscle contract but also to ensure that it is the only muscle that contracts. This way, it will be the only palpably hard structure amidst a sea of soft tissues. The goal of an isolated contraction of the target muscle is not always possible but most of the time it can be attained if the right action - the best action - is chosen.

To do this, we need to know the actions of the adjacent muscles so we can isolate an action for the target muscle. In other words, we need to find an action of the target muscle that is distinct from the actions of the adjacent musculature.

Pectoralis minor is a good example of this. The major action of the pectoralis minor is protraction of the scapula at the scapulocostal joint. But if we ask the client to protract the scapula, the overlying pectoralis major will also contract because it also protracts the scapula. So we need to find a distinct action of the pectoralis minor. The best action to isolate pectoralis minor is downward rotation of the scapula. The client can perform this by extending and adducting the arm at the glenohumeral joint (via scapulohumeral rhythm, extension and/or adduction of the arm requires downward rotation of the scapula) (Figure 2). Using this action, the pectoralis major remains relaxed and loose, and the contraction of the pectoralis minor can be felt through it.

Sometimes the best action varies depending on which part of the target muscle we are palpating. A good example of this is the fibularis longus (FL; formerly named the peroneus longus), located in the lateral leg between the extensor digitorum longus (EDL) which is anterior to it and the soleus which is posterior to it (Figure 3). The FL everts and plantarflexes the foot. So which action is best to choose? That depends on which part of the FL we are palpating. If we are palpating the anterior aspect of the FL, then we need to discern it from the adjacent EDL. In this case, if we ask the client to evert the foot, both muscles will engage (the EDL is also an evtor of the foot) and it will be difficult to discern the FL from the EDL. The better action to choose is plantarflexion of the foot. This will engage the FL, but the EDL will remain relaxed. However, if we are palpating the posterior aspect of the FL, adjacent to the soleus, plantarflexion of the foot is not the wise choice because the soleus also does this action. Here, eversion of the foot is the better choice because it will engage the FL but the soleus will remain relaxed and soft (the soleus is an invertor of the foot).

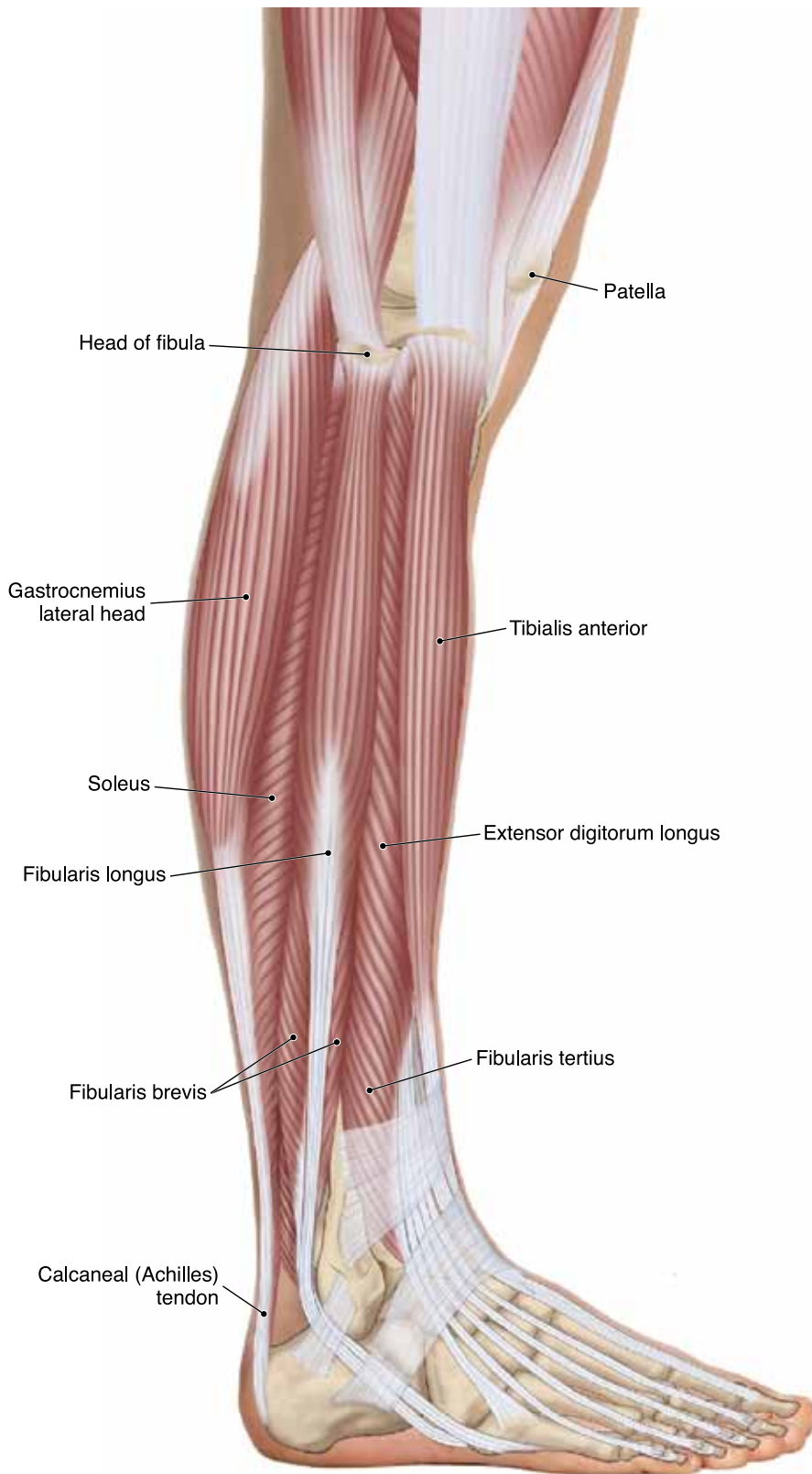


▲ **Figure 2:** Downward rotation of the scapula is the best action to choose to engage and palpate the pectoralis minor. From Muscolino JE: *The Muscle and Bone Palpation Manual, With Trigger Points, Referral Patterns, and Stretching*. St. Louis, 2009, Elsevier. Photo taken by Yanik Chauvin.

### **Guideline 4 - Add resistance**

The point of Guidelines 2 and 3 is to make the target muscle engage and contract so that it hardens. However, if the joint action does not require a sufficiently strong enough contraction, the target muscle might not harden enough to be clearly palpable. This is especially true if the body part being moved is not very heavy or if the direction of motion is not against gravity. For this reason, guideline number 4 is to add resistance to the contraction. In Figure 1, the therapist can be seen adding resistance to the client's distal arm as she attempts to abduct it.

There are two important aspects to be aware of when adding resistance. First is that adding resistance is not a battle between the therapist and client to see who is stronger. The goal is to ask the client to try to move their body part and for the therapist to add just enough resistance to equal the client's contraction so that it is isometric.



▲ **Figure 3:** The fibularis longus is located in the lateral leg between the extensor digitorum longus and the soleus. From Muscolino JE: *The Muscle and Bone Palpation Manual, With Trigger Points, Referral Patterns, and Stretching*. St. Louis, 2009, Elsevier.

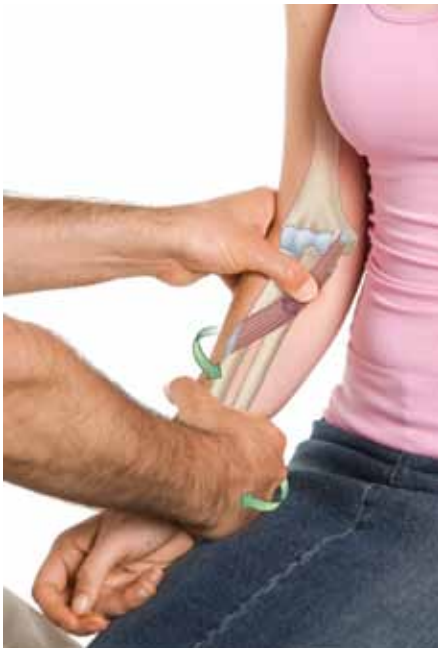If the resistance is not sufficient to clearly palpate the target muscle, then add more resistance by asking the client to press harder until you can feel its contraction. In some cases, it might be better to ask the client to press more gently. What is most important is that you are creative and try different degrees of resistance until you can clearly feel the contraction of the target muscle.

The second aspect of adding resistance during a palpation protocol is where you contact the client when adding the resistance. This is crucially important and is where more mistakes are made in palpation protocols than anywhere else. The rule to follow when contacting the client to add resistance is to never cross a joint that does not need to be crossed.

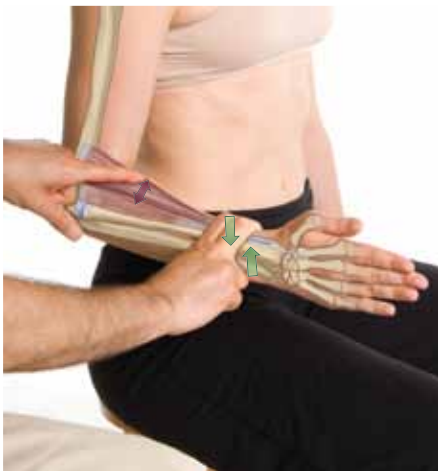In the case of the deltoid, note that the therapist is adding resistance by contacting the client on the distal arm (See Figure 1). He is not crossing the elbow joint to contact the client's forearm or crossing the wrist joint to contact the client's hand.

The reason for this is clear if we keep in mind that the purpose of a palpation protocol is to feel and discern the target muscle from adjacent musculature. If the therapist crosses the elbow joint and contacts the client's forearm, the client will probably engage elbow joint musculature, whose bellies are in the arm next to the distal end of the deltoid (perhaps brachialis or triceps brachii, depending on whether the arm is medially or laterally rotated while abducting). This might cause the therapist's palpating fingers to move off the deltoid onto this other musculature, believing it is still deltoid because it is engaged and palpably hard.

Other examples are the pronator teres and brachioradialis of the forearm. Resistance to pronation of the forearm at the radioulnar joints for the pronator teres should be done by contacting the client's distal forearm, not crossing the wrist joint to contact the client's hand (Figure 4a). If the hand is contacted, the client will contract finger and wrist joint flexor muscles that are located near the pronator teres (flexor carpi radialis is directly adjacent to the pronator teres and the flexors digitorum superficialis and profundus are adjacent and deep to it), making it difficult to discern from these other muscles.



▲ Figure 4a



▲ Figure 4b

The contact point on the client when adding resistance is critically important. Resistance should be added by contacting the client on the distal forearm when palpating the pronator teres (A) and the brachioradialis (B). From Muscolino JE: *The Muscle and Bone Palpation Manual, With Trigger Points, Referral Patterns, and Stretching*. St. Louis, 2009, Elsevier. Photos taken by Yanik Chauvin.

### Additional Muscle Palpation Guidelines

There are many other guidelines that make for effective muscle palpation. Following are an additional 10 palpation guidelines that can improve your palpation skills.

1. Look before you palpate. Many muscles are superficial and readily visible. Before placing your hands on the client, perhaps blocking visual observation of the target muscle's contraction, look first and then place your hands.
2. First find the target muscle in the easiest place possible. It is easier to palpate a muscle from attachment to attachment if you first palpate it in the easiest place possible and then continue to palpate it from there.
3. Strum perpendicularly across the target muscle. It is usually easier to feel a muscle by strumming across it than by palpating along its length. The 'strum' should be large enough to start on one side of the muscle, palpate onto its belly and then fall off the other side.
4. Use baby steps to follow the target muscle. To prevent veering off the target muscle, palpate along it in 'baby steps'. Each step should begin directly adjacent to where you last felt the muscle, in other words, where the last baby step ended.
5. Alternately contract and relax the target muscle. It is the change in palpatory hardness of the target muscle (from soft to hard) that is easiest to feel. So, instead of having the client hold an isometric contraction, ask the client to alternately contract and relax the muscle. Contracting and relaxing approximately every 3-5 seconds usually works well.
6. When appropriate, use reciprocal inhibition. When there is a muscle that is superficial or adjacent to the target muscle and that other muscle has the same actions as the target muscle, reciprocal inhibition can be used to inhibit the contraction of the other muscle. For example, when palpating the brachialis deep to the biceps brachii (both flex the elbow joint), have the client's forearm in pronation as it flexes. This will inhibit the biceps brachii from contracting because it is a supinator, so that the brachialis' contraction can be easily felt.
7. Use appropriate pressure. A common palpation error is using pressure that is too light, especially when palpating deeper structures. However, using pressure that is too deep can lessen your sensitivity and be uncomfortable for the client. Appropriate pressure will vary from muscle to muscle - and for the same muscle - from client to client.
8. For deep palpations, sink slowly into the tissue and have the client breathe. Whenever palpating with greater pressure into deeper tissues, always sink in slowly and have the client focus on slow, deep and even breathing.
9. Close your eyes and construct a mental picture of the client's anatomy under the skin as you palpate. If you close your eyes, you can more easily focus on and mentally visualise the structures that you are palpating under the skin. This will help to guide you towards and along the target structures that you are palpating.
10. Use the optimal palpation position. Each muscle palpation usually has an optimal client position. If the client is not in that position and an accurate palpation is needed, have the client move into that position.

Resistance to flexion of the forearm at the elbow joint for the brachioradialis should also be accomplished by contacting the client's distal forearm, not crossing the wrist joint to contact the hand (Figure 4b). If the hand is contacted instead, the client will contract muscles of radial deviation (abduction) of the hand (extensors carpi radialis longus and brevis) that are located next to the target muscle, making it difficult to discern the brachioradialis from these other muscles.

Applying the four palpation guidelines presented in this article creates the fundamental foundation of muscle palpation. This foundation can be augmented with the additional guidelines that are described briefly in the Additional Muscle Palpation Guidelines Box. But the key to palpation literacy is not to simply apply palpation guidelines in a rote fashion. True palpation literacy comes from learning to critically reason through these guidelines and creatively weave them together as you apply them to the client on the table. This is where the art of palpation literacy and assessment lie, and these skills are at the heart of being an effective and successful clinical orthopaedic massage therapist.

*Joseph E. Muscolino has been a massage therapy educator for 25 years, and a chiropractor in private practice for 26 years. He is the author of The Muscle and Bone Palpation Manual, With Trigger Points, Referral Patterns, and Stretching; The Muscular System Manual, The Skeletal Muscles of the Human Body, 3ed; and Kinesiology, The Skeletal System and Muscle Function, 2ed; as well as the upcoming Advanced Treatment Techniques for the Manual Therapist: Neck. Joseph's books are translated into seven foreign languages.*

*Joseph also teaches continuing professional education courses and is visiting Australia this July. He will be presenting intermediate and advanced treatment techniques workshops for the neck and low back in Sydney and Hobart. For more information, please visit his website at [www.learnmuscles.com](http://www.learnmuscles.com).*

### Motion palpation

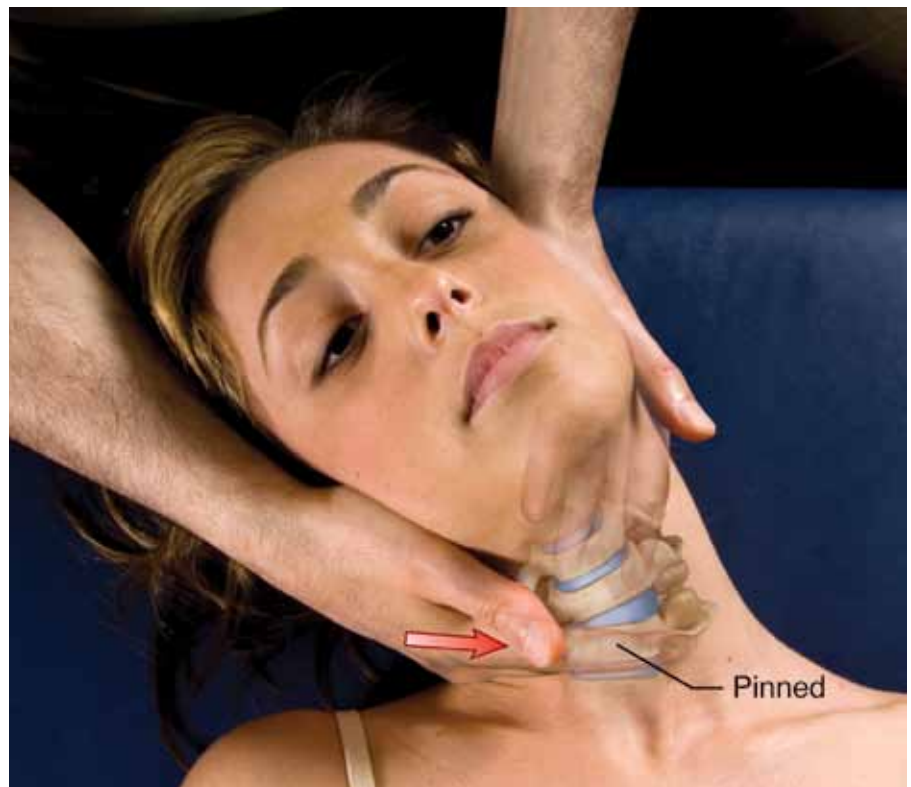This article, and the field of massage therapy in general, focuses on muscle palpation. However, of equal importance is palpation assessment and treatment of the intrinsic fascial soft tissues of the joint. This is especially true when working the neck.

Intrinsic soft tissues of a cervical spinal joint include the fibrous joint capsule and the deep short ligaments (as well as short intrinsic muscles) that are located between adjacent vertebrae. The assessment technique to determine the flexibility/tautness of these structures is called motion palpation.

Motion palpation is performed in a similar manner to pin and stretch technique but applied very precisely. The therapist stabilises one vertebra while challenging the vertebra directly superior to it to move. Figure 5 demonstrates motion palpation of a lower cervical joint level. The therapist uses the radial side of the proximal phalanx of the index finger to pin the lower vertebra of the joint. He then uses his other hand to move the head and the rest of the cervical spine above the pinned vertebra on it until tension is reached at the end of passive range of motion. Once reached, a gentle motion is added, bringing the joint into the range of motion called joint play. This motion/position is held for less than one second and then released. Healthy intrinsic tissues will exhibit a springy end-feel. If springiness is not felt, in other words motion is decreased and the end-feel is locked, then joint mobilisation is indicated.

Joint mobilisation is essentially performed in the exact same manner as motion palpation but the force of the challenge is increased. Joint play and joint mobilisation are extremely valuable clinical orthopaedic assessment and treatment techniques but are best learned at a hands-on workshop where personal instruction and supervision can be given.

Note: If the client has a space-occupying lesion of the cervical spine, such as a pathologic disc or bone spur, a physician's release to perform motion palpation of the region of the spine should be obtained.



▲ **Figure 5:** Motion palpation of a cervical spinal joint. With permission from Muscolino, J. Advanced Treatment Techniques for the Manual Therapist: Neck. Baltimore, MD: Lippincott Williams & Wilkins (forthcoming). Photo taken by Yanik Chauvin.



# FIRM·n·FOLD MASSAGE EQUIPMENT

Superior style, quality and comfort... just relax with a Firm·n·Fold table

Much more than just massage tables, Firm-n-Fold have been supplying quality equipment and accessories to the massage and natural therapies industries for over 25 years. Our web store has over 300 products online.

Visit our website for your chance to win a powerlift table. Browse in one of our showrooms and join our customer reward programme to receive free gifts and discounts on every purchase.



[www.massageequip.com](http://www.massageequip.com)

Brisbane · Melbourne · Sydney · Gold Coast · Ph. 1800 640 524

## NOTICE TO THERAPISTS

Do you hold the Diploma of Remedial Massage?



### Then upgrade to the Advanced Diploma of Remedial Massage (Myotherapy)

(nearby accommodation is available for interstate students)

- OUR INTENSIVE ADRM COURSE IS RUN EVERY WEEKEND OVER 6 MTHS
- INDIVIDUAL TRAINING PLANS AVAILABLE
- ROLLING ENROLMENTS MONTHLY
- DON'T WAIT - COME AND JOIN US



9553 5959 consultant@mti.vic.edu.au www.mti.vic.edu.au

max therapy institute  
Level 1, 18 Station St Moorabbin VIC 3189

## Deep Tissue Massage, Stretching & Joint Mobilization with Dr. Joe Muscolino

**AMT Approved CEU**



Join a unique experience to train with Dr. Joe Muscolino, a licensed chiropractic physician with 24 years of experience as a massage therapy educator, and author of the best selling book "The Muscle and Bone Palpation Manual"

Intermediate & Advanced Techniques for the Neck  
Intermediate & Advanced Techniques for the Low Back & Pelvis  
Sydney (2-3 July & 4-5 July), Hobart (9-10 July)

Register Now at: [www.terrarosa.com.au](http://www.terrarosa.com.au)  
Email: [terrarosa@gmail.com](mailto:terrarosa@gmail.com) or call 0402 05 95 70

For terms & Conditions see: [www.terrarosa.com.au](http://www.terrarosa.com.au)

